

The sequelae of a neglected thoracolumbar cystic spinal lesion

¹Zhen Qiang Goo, ¹Sutharshan Sockalingam, ¹Chun Yoong Cham, ²Raja Rizal Azman Bin Raja Aman, ³Jeyaganesh Veerakumaran, ¹Dharmendra Ganesan

¹Division of Neurosurgery, Department of Surgery, ²Department of Biomedical Imaging, ³Department of Anesthesiology, University of Malaya, Kuala Lumpur, Malaysia.

Abstract

Large thoracolumbar intradural cystic lesions are rare. The possible diagnosis would be a cystic nerve sheath tumour, dural ectasia or arachnoid cyst. We report the first case of a neglected giant thoracolumbar spinal cystic tumour that had resulted in progressive deleterious spinal column deformity due to bony erosion precluding any form of surgical remedy. In the same case, another fatal sequela of a neglected spinal cystic tumour is a spontaneous rupture resulting in an acute hydrocephalus and mortality. This case impresses the natural history of a spinal cystic lesion. The take home point would be these cases need early surgical intervention is indicated to prevent sequelae that has been described.

Keywords: Lumbar tumour, lumbar cystic tumour, hydrocephalus

INTRODUCTION

Benign tumour that arises from the nerve roots of the spinal cord can be either schwannoma or neurofibroma. An entirely cystic appearance of a nerve sheath tumours of the spine is extremely rare. There are only 12 cases of lumbar spinal cystic schwannomas that have been reported in literature.¹⁻¹³ Other differential diagnoses of radiological cystic lesion would be arachnoid cysts or dural ectasia.^{14,15} Most of these are asymptomatic and are discovered incidentally.

In a case series of 187 cases of spinal schwannomas, 20% of the patients were asymptomatic. The other 80% of the patients have complaints such as local pain, radiating pain, paraparesis, radicular deficit, sensory deficit and difficulty voiding. Late complication occurred in 21% of the patients, which include cystic myelopathy, spinal arachnoiditis, spinal deformity and chronic pain. These patients generally have normal life expectancies.¹⁶

Fatal complications related to benign lumbar spinal nerve sheath such as schwannomas have not been reported. We are reporting the first case of a neglected giant lumbar spinal cystic tumour most probably a cystic schwannoma that resulted in severe spinal deformity and eventually ruptured causing acute hydrocephalus.

CASE REPORT

A seventeen-years old boy who was a refugee from the Middle East had a history of progressive lower limb weakness since the age of ten years old. The past medical history indicates surgery followed by further treatment for hepatoblastoma at 4 years of age in Europe. MRI images of the spine performed in January 2014 while in the Middle East (Figure 1A, 1B) shows a large intradural cyst with minimal peripheral enhancement extending from the entire lumbar spine to the lower thoracic spine. There was scalloping of the lumbar vertebral bodies with early formation of kyphosis. At that point, he was managed conservatively as a case of extensive lumbar dural ectasia.

The MRI imaging that was performed in August 2016 (Figure 1C) shows a more pronounced scalloping of the lumbar vertebral bodies as well as development of an acute thoracolumbar kyphosis. He was still managed conservatively. He became wheelchair bound at the middle of 2017. He had urinary urgency with occasional urinary incontinence associated with constipation.

His first presentation to our clinic was in September 2018. He was able to independently perform a wheelchair transfer. There was only a slight lateral movement of the thighs (MRC Grade 2) with no movement of the lower limbs.

Address correspondence to: Zhen Qiang Goo, Department of Surgery, University of Malaya, Kuala Lumpur, Malaysia. Email: zhenqiang@ummc.edu.my

Date of Submission: 19 August 2021; Date of Acceptance: 4 September 2021

<https://doi.org/10.54029/2022yzd>

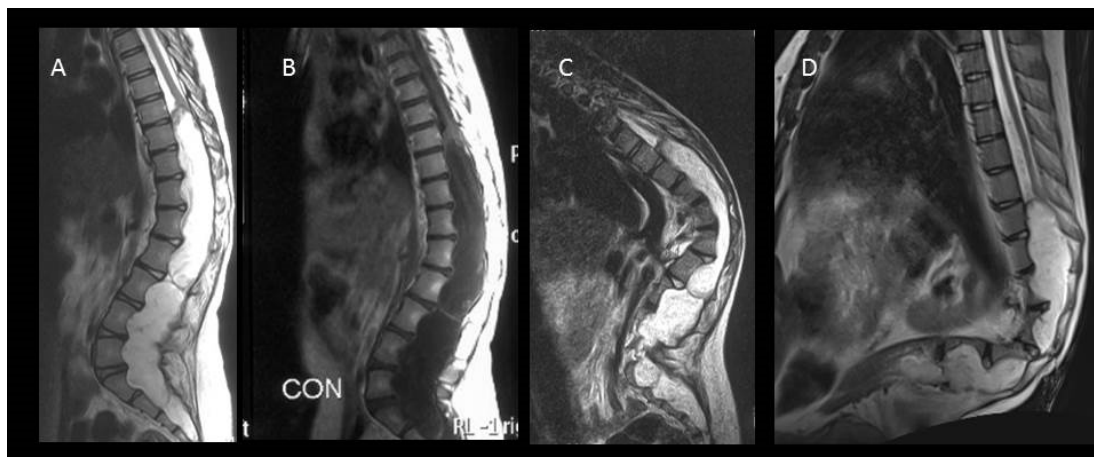


Figure 1. Sagittal MRI images of the spine T2W (A) T1W-post gadolinium (B) from 2014, T2W from 2016 (C), and T2W from 2018 (D). Images show a large cystic lesion occupying the lower thoracic, lumbar and sacral spinal canal with minimal enhancing septation causing increasing scalloping of the vertebral bodies and worsening kyphosis.

The thighs and calf musculature were atrophic bilaterally. There was a sensory level at about mid-thigh bilaterally. He had a significant hump at the thoracolumbar region.

The MRI brain carried out in September 2018 showed normal brain architecture with normal ventricles (Figure 2). The MRI of the thoracic and lumbosacral spine (Figure 1D) showed progressive enlargement of the intradural cyst with more thinning of the lower thoracic and lumbar vertebral bodies. There was no evidence of any enhancement within the cyst. There was

an acute kyphotic deformity between T12 and L1 vertebra. The differential diagnosis was cystic schwannoma or arachnoid cyst.

The CT scan of the spine in September 2018 (Figure 3A, 3B) shows marked scalloping of the posterior part of the T10 to S3 vertebral bodies. There was acute kyphosis at the T12-L1 junction with critical stenosis of the canal. The expansile nature of the cyst has resulted in marked thinning of the lumbar vertebra pedicles. The laminae and the facet joints were also almost “egg shell” thinness.

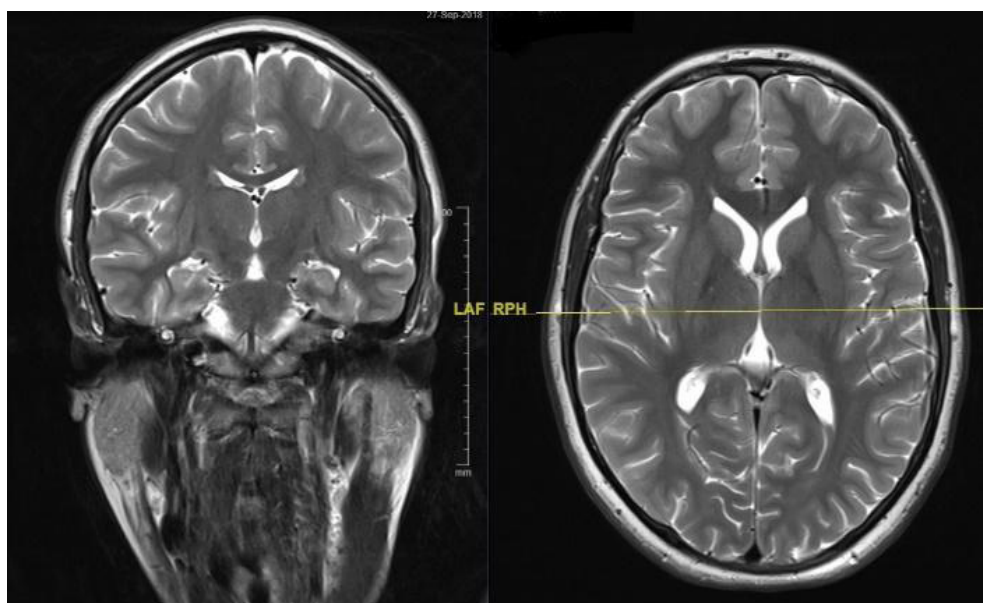


Figure 2. MRI images of the brain from 2018. Images show normal brain architecture with normal ventricles.

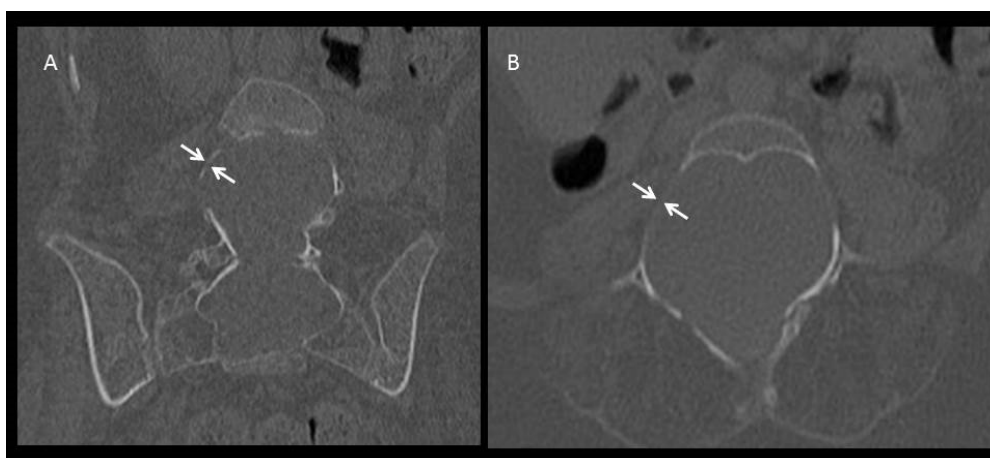


Figure 3. Coronal (A) and axial (B) CT images of the L5 vertebra showing severe thinning of the pedicle (white arrows).

The disease progression over the 5 years period was fairly extensive resulting in the thinning of the respective vertebra circumferentially making it challenging to offer any viable surgical options. Inevitably, the excision of the lesion will need to follow with spinal reconstruction and stabilization which was a tall order considering the anatomical structure of the spine. A conservative management strategy was employed and the family was counselled on the nature of the condition and the reason for taking on such an approach. He was monitored clinically on a six-monthly basis.

In December 2019, he came to the emergency department with a new onset of generalized tonic,

clonic seizure which after 5 minutes aborted spontaneously. His parents added that he had been complaining of progressively worsening headaches associated with vomiting for 3 days prior to the seizure. His pulse rate was 80 beats per minute and blood pressure was 110/72 mmHg. He was afebrile.

His serum electrolytes were within normal range. Serum C-reactive protein was 10.77 mg/L (Normal: < 5.0 mg/L). His total white cell count was 8.4×10^9 (Normal: 4.0-10.0) and platelet count was 271×10^9 (Normal 150-400). The plain CT scan brain showed enlarged ventricles indicating communicating hydrocephalus (Figure 4).

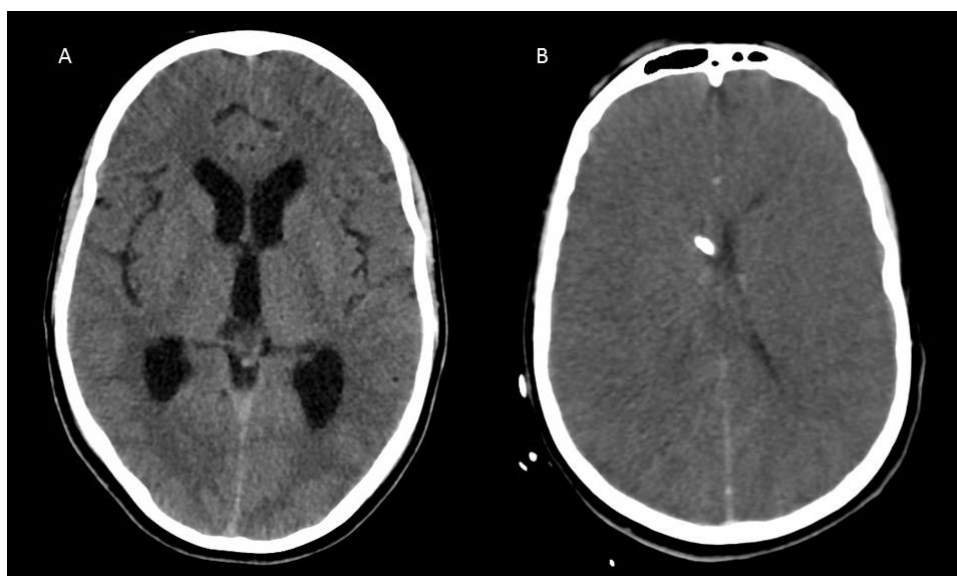


Figure 4. Axial CT images of brain showing communicating hydrocephalus (A) and slit like ventricles following insertion of an external ventricular drain (EVD) (B).

An emergency external ventricular drain (EVD) was inserted. There was a very viscid cerebrospinal fluid (CSF) that was drained which was of moderate pressure. The EVD was blocked as soon as he returned to the neuro-intensive care unit. The repeated plain CT-brain showed EVD within the ventricles with slit like ventricles (Figure 4B). The drained fluid was viscid and clotted that the microscopy assessment could not be conducted. He succumbed within 36 hours of presentation.

DISCUSSION

Sridhar *et al.* proposed a classification for spinal schwannomas, in that proposed classification, a giant spinal schwannoma is a schwannoma that extend over more than two vertebral levels (Type II), those with an extraspinal extension of more than 2.5cm (Type IVb) or those with lesions that erode the vertebral bodies and extend laterally and posteriorly into the myofascial planes (Type V- giant invasive).¹⁷ Their study achieved radical excision with good results, however all patients required fusion, and some patients needed additional stabilization procedures. The cystic lesion that we present is be classified as type IVb. It extends from T10 to S3 of the spinal canal. It insinuates the conus medullaris. The bony canal of exit foramina is stretched and thinned, with the cystic lesion within the spinal canal. There is no extraspinal or myofascial extension.

There are a few histological variants of spinal schwannomas that have been described in the literature, namely cellular, melanotic and plexiform.¹⁸⁻²⁰ Cystic changes of schwannomas are hypothesized to be due to mucinous degeneration, ischemic necrosis, haemorrhage, and the formation of and subsequent coalescence of microcysts. The presence of a spinal schwannoma with total cystic components are exceedingly rare. Till date, only less than 12 of spinal schwannoma with total cystic component have been reported.^{1,2,4-9,11-13} The combination of a giant spinal schwannoma with a dominant cystic component is exceedingly rare, there are only 3 reported cases prior to our case report.²¹

Delayed presentation is common because of the slow growing nature of schwannomas. The most common presentation is low back pain. Occasionally a giant schwannoma can cause progressive pain, neurological deficits, and involvement of nerve roots. Rare acute complications such as intracranial subarachnoid haemorrhage, hydrocephalus without tumour rupture, or even traumatic intra-tumoural

haemorrhages have been reported.^{2,8,9,22}

The serial MRI spine images over the 5 years period (Figure 1) showed a large intradural thoracolumbar cystic lesion. There was clear progression of kyphotic deformity as well as clinical neurological deficits. The MRI thoracolumbar spine T2 weighted axial view shows the predominant cystic lesion with expanded spinal canal (Figure 6). The differential diagnosis in the context of the radiological findings (Figure 1 and Figure 3) would be a cystic benign tumour, dural ectasia or arachnoid cyst. The fact, that the initial MRI in 2014 showed septation within the cyst and faint peripheral enhancement of the cyst, the most probable radiological diagnosis would be a cystic schwannoma. A case reported²³ with almost similar MRI imaging findings (Figure 5) and the patient had undergone surgical excision and stabilization with histology showing an Antoni – A type schwannoma. Verdelhan *et al.* in his paper on MRI appearance of schwannoma suggested that a spinal intradural extramedullary tumour with hyperintensity on T2W images or intense enhancement without “dural tail sign” should be considered as a schwannoma.²⁴ The case we describe has no histological confirmation but the radiological diagnosis is a convincing of a cystic intradural tumour most probably a cystic schwannoma.

The clinical presentation of headache and sudden seizure with the CT scan brain (Figure 4A) compared to one of the routine MRI brain (Figure 2) shows an acute hydrocephalus. The most plausible postulation would be that the large cystic spinal schwannoma had ruptured spontaneously into the subarachnoid space resulting in development of acute hydrocephalus. The external ventricular drained a viscid fluid which coagulated within the tube within minutes indicating the cerebrospinal fluid is contaminated with high proteinaceous fluid. The ruptured cystic fluid would have contained mucinous material and other chemical products that could have initiated and aggravated the generalized seizure. He succumbed to this complication. Since the fluid coagulated there was no fluid for microscopy or biochemical examination. A case of dural ectasia or arachnoid cyst would not present such manner as the content of these lesions are cerebrospinal fluid.

In conclusion, this case illustrates the natural history of a benign lumbar spinal cystic tumour. In asymptomatic cases (incidental) with a spinal cystic tumour, it would be sensible to proceed for early surgical excision once the radiological

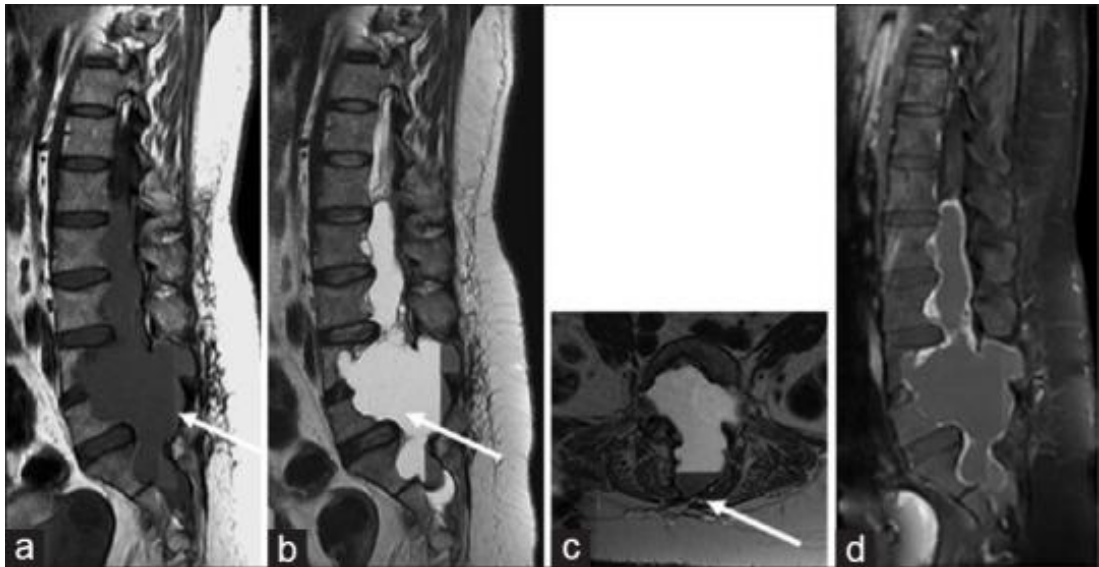

Figure 5. A case of giant cystic schwannoma of the cauda equina reported by Himmiche et al.²³ The sagittal MRI images show similar hyperintensity on T2W (b). It was histologically confirmed as Antoni-A type schwannoma. (Himmiche M, Benzagmout M, Alami B, Benabdellah IS, Chakour K, Chaoui ME. Giant cystic schwannoma of the cauda equina. *Ann Afr Med*. 2019;18(3):180-3.)

diagnosis is conclusive or surveillance imaging shows progression of the cystic lesion. This case illustrates very eloquently the consequence of neglecting treatment at an early stage of presentation. The disease caused disabling neurological deficits. The disease had progressed to the point that surgical remedy was not possible by virtue of significant destruction of spinal

column architecture. Unfortunately, he succumbed most probably to the rupture of the cyst into the subarachnoid cyst resulting in a fatal acute hydrocephalus.

DISCLOSURE

Conflict of interest: None

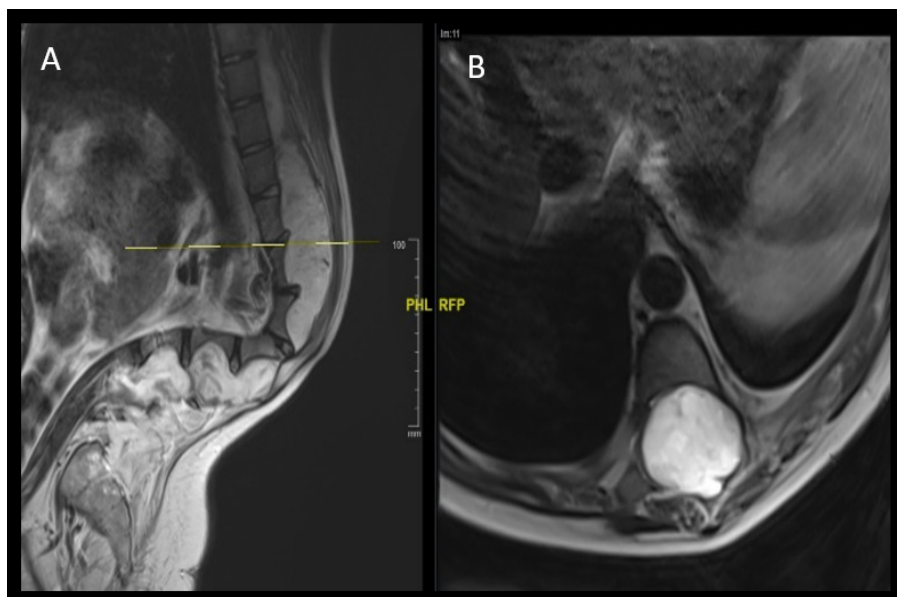


Figure 6. Sagittal MRI images of the spine T2W (A) and Axial MRI image of spine T2W (B). Images show a large cystic lesion with hyperintensity on T2W and expanding the spinal canal significantly.

REFERENCES

1. Akhaddar A, Ajja A, Albouzidi A, Elmostarchid B, Boucetta M. Cystic schwannoma of the cauda equina mimicking hemangioblastoma. *Neurochirurgie* 2008;54(2):101-3.DOI: 10.1016/j.neuchi.2008.01.007.
2. Bauer M, Brock M, Cervos-Navarro J, Prosenc N, Marx P. [Intraspinal neurinoma in the thoracolumbar junction presenting unusual symptoms. The differential diagnosis of lumbago]. *Dtsch Med Wochenschr* 1994;119(17):628-30.DOI: 10.1055/s-2008-1058740.
3. Borges G, Bonilha L, Proa M, Jr., et al. Imaging features and treatment of an intradural lumbar cystic schwannoma. *Arq Neuropsiquiatr* 2005;63(3A):681-4.DOI: 10.1590/s0004-282x2005000400025.
4. Corley J, Kasliwal MK, O'Toole JE, Byrne RW. Extensive vertebral scalloping in a case of giant cystic spinal schwannoma: more than just a radiological diagnosis. *J Neurooncol* 2014;120(1):219-20.DOI: 10.1007/s11060-014-1532-0.
5. Hamabe F, Soga S, Imabayashi H, Matsunaga A, Shinmoto H. Mobile spinal schwannoma with a completely cystic appearance. *Am J Case Rep* 2019;20:859-63.DOI: 10.12659/AJCR.916249.
6. Hsieh CT, Tsai WC, Liu MY. Intradural lumbar cystic schwannoma. *Neurosciences (Riyadh)*. 2011;16(4):366-8.
7. Jaiswal A, Shetty AP, Rajasekaran S. Giant cystic intradural schwannoma in the lumbosacral region: a case report. *J Orthop Surg (Hong Kong)* 2008;16(1):102-6. DOI: 10.1177/230949900801600124.
8. Jenkins AL, 3rd, Ahuja A, Oliff AH, Sobotka S. Spinal schwannoma presenting due to torsion and hemorrhage: case report and review of literature. *Spine J* 2015;15(8):e1-4.DOI: 10.1016/j.spinee.2015.04.046.
9. Karaca L, Sade R, Yuce I, Ogul H, Bayraktutan U, Kantarci M. Spinal cystic schwannoma causing neurogenic claudication. *Spine J* 2015;15(12):e3-4. DOI: 10.1016/j.spinee.2015.06.063.
10. Kasliwal MK, Kale SS, Sharma BS, Suri V. Totally cystic intradural extramedullary schwannoma. *Turk Neurosurg*. 2008 Oct;18(4):404-6.
11. Netra R, Hui MS, Gang MZ, Ming Z. Spinal cystic schwannoma: an MRI evaluation. *J Coll Physicians Surg Pak* 2014;24(2):145-7.DOI: 02.2014/JCPSP.145147.
12. Santin-Amo JM, Serramito-Garcia R, Agulleiro-Diaz JP, Gelabert-Gonzalez M, Vazquez-Herrero F. [Cystic schwannoma of the spine]. *Rev Neurol* 2015;60(7):329-30.
13. Wu D, Ba Z, Huang Y, Zhao W, Shen B, Kan H. Totally cystic schwannoma of the lumbar spine. *Orthopedics* 2013;36(5):e679-82.DOI: 10.3928/01477447-20130426-36.
14. Khosla A, Wippold FJ, 2nd. CT myelography and MR imaging of extramedullary cysts of the spinal canal in adult and pediatric patients. *AJR Am J Roentgenol* 2002;178(1):201-7.DOI: 10.2214/ajr.178.1.1780201.
15. Lundby R, Rand-Hendriksen S, Hald JK, et al. Dural ectasia in Marfan syndrome: A case control study. *Am J Neuroradiol* 2009;30(8):1534-40.DOI: 10.3174/ajnr.A1620.
16. Seppala MT, Haltia MJ, Sankila RJ, Jaaskelainen JE, Heiskanen O. Long-term outcome after removal of spinal schwannoma: a clinicopathological study of 187 cases. *J Neurosurg* 1995;83(4):621-6.DOI: 10.3171/jns.1995.83.4.0621.
17. Sridhar K, Ramamurthi R, Vasudevan MC, Ramamurthi B. Giant invasive spinal schwannomas: definition and surgical management. *J Neurosurg* 2001;94(2 Suppl):210-5.DOI: 10.3171/spi.2001.94.2.0210.
18. Font RL, Truong LD. Melanotic schwannoma of soft tissues. Electron-microscopic observations and review of literature. *Am J Surg Pathol* 1984;8(2):129-38.DOI: 10.1097/00000478-198402000-00007.
19. Woodruff JM, Godwin TA, Erlandson RA, Susin M, Martini N. Cellular schwannoma: a variety of schwannoma sometimes mistaken for a malignant tumor. *Am J Surg Pathol* 1981;5(8):733-44.
20. Woodruff JM, Marshall ML, Godwin TA, Funkhouser JW, Thompson NJ, Erlandson RA. Plexiform (multinodular) schwannoma. A tumor simulating the plexiform neurofibroma. *Am J Surg Pathol* 1983;7(7):691-7.DOI: 10.1097/00000478-198310000-00009.
21. Wilkinson JS, Mann SA, Robinson CA, Fournay DR. Giant cystic intradural lumbosacral schwannoma: is stabilization necessary? *Can J Neurol Sci* 2010;37(4):535-8.DOI: 10.1017/s0317167100010623.
22. Gandhoke CS, Syal SK, Singh D, Batra V, Nallacheruvu Y. Cervical C2 to C4 schwannoma with intratumoral hemorrhage presenting as acute spastic quadriplegia: A rare case report. *Surg Neurol Int* 2018;9:142.DOI: 10.4103/sni.sni_171_18.
23. Himmiche M, Benzagmout M, Alami B, Benabdellah IS, Chakour K, Chaoui ME. Giant cystic schwannoma of the cauda equina. *Ann Afr Med* 2019;18(3):180-3. DOI: 10.4103/aam.aam_61_18.
24. De Verdelhan O, Haegelen C, Carsin-Nicol B, Riffaud L, Amlashi SF, Brassier G, et al. MR imaging features of spinal schwannomas and meningiomas. *J Neuroradiol* 2005;32(1):42-9.DOI: 10.1016/s0150-9861(05)83021-4.