

Psychogenic astasia-abasia: A case of unsteady gait

Charles Chan-Chung *FAMS*, Yeow-Hoay Koh *MD*, Eng-King Tan *MD*

Department of Neurology, National Neuroscience Institute – SGH Campus, Duke-NUS Medical School, Singapore

Abstract

Falls remain common health problems that our elderly population has to face in their daily life, contributing significantly to their morbidity. Patients with astasia-abasia should be recognized promptly though it is uncommon in Singapore. We report a case of a middle-aged lady who presented with psychogenic astasia-abasia. We will illustrate this case with the exhibition of a video showing her gait pre- and post-interventions. Consent was obtained from the patient. Our patient received a multi-disciplinary level of care, including physiotherapy and psycho-education with good response. We performed a non-systematic literature review and we hereby review its description and management.

Keywords: Astasia-abasia, psychogenic movement disorders, unsteady gait, falls

INTRODUCTION

Falls are common problems that our elderly population have to face in their daily life, contributing significantly to their morbidity.¹ Different gait patterns have been described, including spastic gait, parkinsonian gait, cerebellar ataxic gait, sensory ataxic gait, frontal and functional gait. It is thus important to recognize the different gait disorders to allow for proper management. We hereby present a case of an unusual gait pattern.

CASE REPORT

A woman aged 65-year-old presented to our tertiary centre with a 2-day history of unsteadiness and a tendency to falls. She had complained of a non-specific headache the night before which did not improve the following day. Instead, she developed paraesthesia starting in the left upper limb which then spread to the left lower limb. The sensory symptoms lasted 30 minutes and were associated with the sensation of near syncope and nausea. These symptoms developed while she was sitting down performing her usual prayers. She denied any facial asymmetry, dysarthria, or limb weakness. Following the above symptoms, she subsequently developed an unsteady gait with near falls.

Upon admission, gait examination revealed that she had difficulty with ambulation in that her body would sway in various directions

without ever falling. However, she was noted to be able to sit up and stand independently from a supine position. We have annexed a video of her gait when assessed in the ward (Video 1). Neurological examination, including tone, motor power, sensation to pinprick, proprioception, and vibration, were unremarkable. In addition, no cranial neuropathies were found and there was no evidence of cerebellar dysfunction (such as nystagmus, dysmetria, dysdiadochokinesia, as well as normal heel-shin testing). Fundoscopy was also normal. There were no features to suggest Parkinsonism such as tremor, bradykinesia, and cogwheel rigidity. Supine and standing blood pressure did not show any significant postural hypotension.

With regards to her previous medical history, she had a known background of right hemithyroidectomy in the 1990s and a traumatic right sylvian subarachnoid haemorrhage in 2013. She denied any previous psychiatric history or recent stressors.

She underwent an extensive workup. Laboratory testing included: Folate > 50.5 nmol/L, vitamin B12 1023 pmol/L, free T3 5.3 pmol/L, free T4 9.3 pmol/L, thyroid-stimulating hormone (TSH) 12.1 MU/L. Thyroid peroxidase (TPO) antibodies were normal. Serum paraneoplastic panel [Hu, Yo, Ri, CV2, Amphiphysin, PNMA2/Ta, Recoverin, SOX1, Titin, Zic4, GAD65, and Tr (DNER)] and autoimmune encephalitis panel (NMDA-R, CASPR2, LGI, AMPAR 1/2,

Address correspondence to: Charles Chan-Chung FAMS, National Neuroscience Institute, Duke-NUS Medical School, Outram Road, Singapore 169608. Email: dr.charles.chan.chung@gmail.com

Date of Submission: 2 September 2021; Date of Acceptance: 3 October 2021

<https://doi.org/10.54029/2022fcu>

DPPX, GABABR) were negative. Magnetic resonance imaging (MRI) of the brain was mostly unremarkable, except for a few non-specific T2 hyperintense foci in the cerebral white matter. The diffuse weighted imaging (DWI) sequence of the MRI brain did not reveal any acute stroke. MRI of the cervical-thoracic-lumbar spine showed degenerative spondylosis, with mild central canal stenosis at C5-6 and C6-7, and L4-5 mild central canal stenosis.

Further neurophysiological tests were carried out. Transcranial magnetic stimulation (TMS) study showed normal central motor conduction time (CMCT) and motor evoked potentials (MEP) to both upper and lower limbs. Nerve conduction study (NCS) showed left S1 radiculopathy and mild right carpal tunnel syndrome. Needle electromyography (EMG) was unremarkable.

Polygraphic EMG test was performed with surface electrodes recording at bilateral tibialis anterior (TA) and medial gastrocnemius (MG) muscles. The polygraphic EMG test was designed

to look for orthostatic tremor (with recordings at rest, while standing, during ambulation, during isotonic contraction of both lower limbs, and with both hands leaning over a chair). It was also designed to look for functional movement disorder (with recordings at rest, during cognitive tasks, with ballistic movements of the arm, and finger tapping synchronised to metronome sequences). There were no features to suggest orthostatic tremors in the recordings, such as high-frequency tremors of the legs while standing and during isotonic contraction. The study showed non-synchronous EMG bursts of variable duration recorded over both TA and MG muscles while standing. These were attenuated with mental distraction, ballistic movements of the arm, and finger tapping synchronised to metronome sequences (Figure 1 A-D). The polygraphic EMG study showed evidence of variability and distractibility, suggestive of a functional movement disorder.

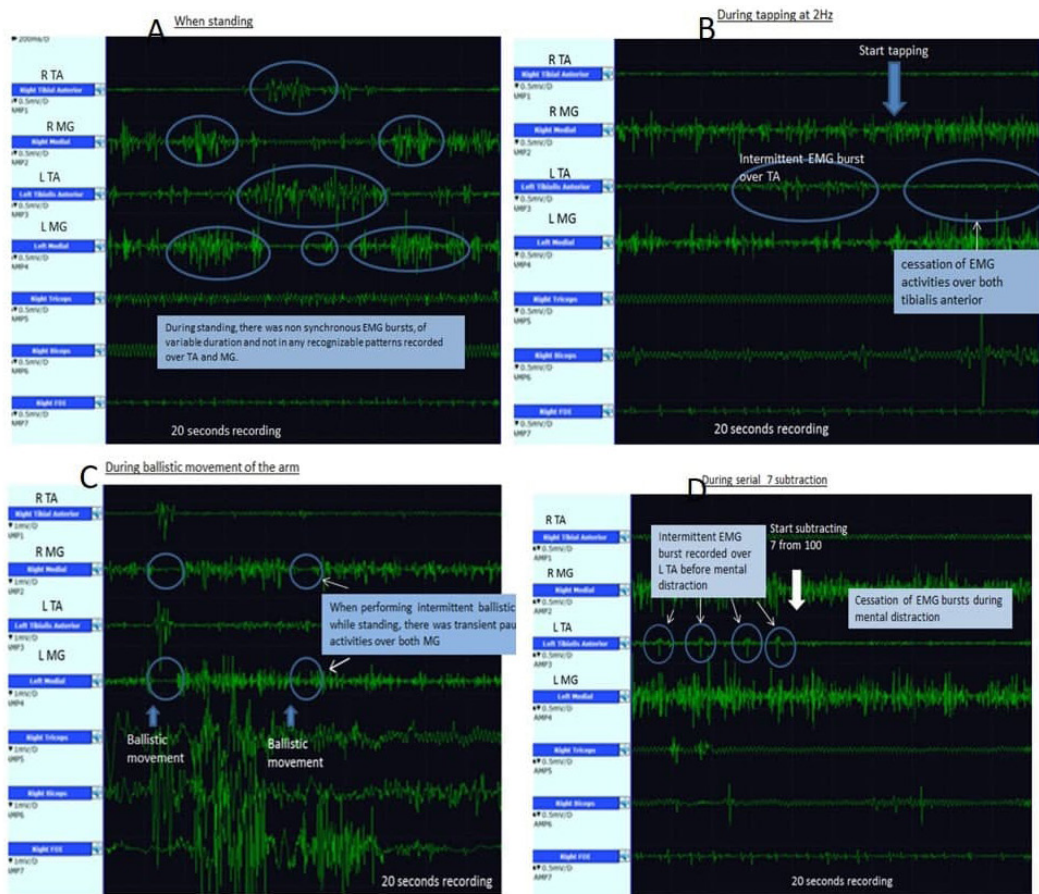


Figure 1. Lower Limb surface EMG (A) When standing (B) During finger tapping (C) During ballistic movement of the arm (D) During serial 7 subtraction.

R: Right, L: Left, TA: Tibialis Anterior, MG: Medial Gastrocnemius

Our impression was that of a psychogenic astasia-abasia. We have counselled the patient using re-education and positive suggestion. The patient was referred to the physiotherapist and occupational therapist for gait training. She improved after 24 hours and was deemed fit for discharge. We have annexed a video of her gait on discharge (Video 2). She remained well three months post-discharge.

DISCUSSION

Proper evaluation of gait disorders can be challenging to an inexperienced physician. Different gait patterns have been described, including spastic, parkinsonian, cerebellar ataxic, sensory ataxic, frontal, and functional gaits. When assessing gait, we should note the velocity (distance covered in a given time), cadence (steps per minute), stride length (distance covered by gait cycle), step length (distance covered during the swing phase of a single leg), and step width (distance between the left and right feet while walking).³

Functional gait disorders remain a diagnostic challenge more than ever since they have a heterogeneous presentation.^{4,5} They were previously referred to as “psychogenic,” but there are often no known precipitating stressors. Baik and Lang established that 5.7% of patients with psychogenic movement disorders had pure functional gait disorder.⁶

Electrophysiologic tests using polygraphic EMG and accelerometer are valuable tools to study the phenomenology of functional movement disorders. Polygraphic EMG can

record the presence of variability, inconsistency, distractibility, and entrainment. In addition, polygraphic EMG with power spectrum and coherence analysis is also necessary to diagnose conditions, such as orthostatic tremor (OT) and orthostatic myoclonus (OM).⁷ Differentiating between OT and OM can be difficult clinically because both can present with frequent falls and unsteady gait which can sometimes appear bizarre enough to mimic functional gait disorders. In our case described above, there were no electrophysiologic features to suggest either an orthostatic tremor or orthostatic myoclonus.

Astasia-abasia is a Greek term that refers to the inability to stand and to walk. It was first described in 1888 by Paul Blocq, who was an “*interne des hôpitaux*” at the Salpêtrière.⁸ Blocq’s original description insisted on the inability to use the lower limbs during standing while this use was normal in the plane of the bed.^{8,9} Initially considered a pure functional disorder, it is now a descriptive term since organic gait disorders can mimic this presentation. An excellent approach to astasia-abasia had been proposed previously, whereby cases are divided into psychogenic and non-psychogenic causes.¹⁰ Table 1 summarizes the key clinical characteristics of psychogenic astasia-abasia.¹⁰

Astasia-abasia is difficult to manage with a particular concern for the risk of falls. Managing those patients require a multipronged approach. Re-education with positive suggestions aims to restore confidence in the walking abilities, which is important in cases of psychogenic astasia-abasia. Walking aids (such as walking

Table 1. Clinical characteristics of Psychogenic Astasia-abasia

Sudden onset
History of minor trauma
Excessive slowness of movements
Hesitations and pauses
Uneconomic postures (<i>narrow base of support, “at the edges” imbalance control</i>)
Appropriate parachute reactions
Genuflexion without fall
Psychogenic “Romberg’s sign” (<i>constant falls irrespective of position but avoided by clutching the physician, large amplitude body sway, improvement of postural balance with distraction</i>)
Tightrope walker posture (<i>arms in abduction and extension</i>)
Manifestations suggestive of great effort (<i>grimaces, pain report</i>)
Associated psychogenic manifestations (<i>psychogenic stuttering, psychogenic tremor</i>)

Adapted with permission from Vercueil (2010)¹⁰

sticks, walking frames, crutches) may be helpful to reassure the patient. Psychiatric input may be required in some cases, especially where there are concomitant psychiatric disorders.^{11,12} If psychiatric input is necessary, the primary physician should emphasize that this is done to help the patient rather than abandon them.

Rarely, some physicians have used the “placebo effect” to both diagnose and treat a patient. This practice has been challenged on ethical grounds, especially if it involves patient deception. Some authors have argued the use of a placebo can be justified by offering a ‘way out of the psychogenic disorder’.¹⁰ This is thought to possibly be more helpful in cases of shorter duration than chronic cases, but level 1 evidence is presently lacking.¹²

In conclusion, falls are a significant contributor to morbidity in our elderly population. Recognizing gait disorders is essential but rendered more difficult with the presence of functional gait disorders. The ability to identify astasia-abasia early will help to facilitate a coordinated and holistic management for these patients.

ACKNOWLEDGEMENT

Many thanks to Dr. Laurent Vercueil (CHU de Grenoble) and Elsevier Masson (PARIS) for permitting the reproduction of their materials.

DISCLOSURE

Conflict of interest: None

Video 1. This video illustrates the patient getting up from a sitting position and trying to ambulate. The patient is seen with knee buckling and anti-economic postures.

Video 2. This video was taken on the day of discharge. It shows significant improvement in gait.

REFERENCES

1. Guideline for the prevention of falls in older persons. American Geriatrics Society, British Geriatrics Society, and American Academy of Orthopaedic Surgeons Panel on Falls Prevention. *J Am Geriatr Soc* 2001;49(5):664-72. doi:10.1046/j.1532-5415.2001.49115.x.
2. Pirker W, Katzenschlager R. Gait disorders in adults and the elderly: a clinical guide. *Wien Klin Wochenschr* 2016;129:81-95. doi:10.1007/s00508-016-1096-4.
3. Jessica M. Baker. Gait disorders. *Am J Med*; 2018;131:602-7. <https://doi.org/10.1016/j.amjmed.2017.11.051>
4. Baizabal-Carvalho JF, Alonso-Juarez M, Jankovic J. Functional gait disorders, clinical phenomenology, and classification. *Neurol Sci*. 2020 Apr;41(4):911-915. doi: 10.1007/s10072-019-04185-8.
5. Nonnekes J, Ruzicka E, Serranov ́a T, Reich SG, Bloem BR, Hallett M. Functional gait disorders – A sign-based approach. *Neurology* 2020;94:1093-9. doi:10.1212/WNL.0000000000009649.
6. Baik JS, Lang AE. Gait abnormalities in psychogenic movement disorders. *Mov Disord* 2007;22:395-9. doi: 10.1002/mds.21283.
7. Edwards MJ, Bhatia KP. Functional (psychogenic) movement disorders: merging mind and brain. *Lancet Neurol* (2012) 11(3):250-60. doi:10.1016/S1474-4422(11)70310-6
8. Blocq P. Sur une affection caractérisée par de l’astasia et de l’abasia. *Arch Neurol (Paris)* 1888;15:24-51, 187-211.
9. Okun MS, Koehler PJ. Paul Blocq and (psychogenic) astasia abasia. *Mov Disord*. 2007 Jul 30;22(10):1373-1378. doi: 10.1002/mds.21474.
10. Vercueil L. Astasia-abasia: causes psychogène et non-psychogènes. *Revue Neurologique* 2010;166:221-8. doi: 10.1016/j.neurol.2009.08.004.
11. Warwick HM, Salkovskis PM. Hypochondriasis. *Behav Res Ther*. 1990;28(2):105-17. doi: 10.1016/0005-7967(90)90023-c.
12. Shapiro AP, Teasell RW. Behavioural interventions in the rehabilitation of acute v. chronic non-organic (conversion/factitious) motor disorders. *Br J Psychiatry*. 2004 Aug;185:140-6. doi: 10.1192/bjp.185.2.140.