

CASE REPORTS

Ischemic stroke due to spontaneous reversible extracranial internal carotid artery vasospasm: A case report

Zeynep Özdemir, Aysun Soysal

Neurology Department, Bakirkoy Prof. Dr. Mazhar Osman Education and Research Hospital for Psychiatric and Neurological Diseases, Istanbul, Turkey

Abstract

Reversible idiopathic extracranial internal carotid artery (ICA) vasospasm is a rare cause of ischemic stroke especially seen among young patients and the pathophysiology is not fully understood. We report here a 23-year-old female who presented with left hemiparesis and hemihypoesthesia. She had several similar reversible attacks which last about 30 minutes in the past years. She had migraine-type headaches five times a month and history of bipolar disease. MRI showed multiple infarction areas on the right middle cerebral artery (MCA) territory with no large vessel abnormality. We could not find any cardioembolic or other etiology except for a PAI-1 heterozygote 4G/5G mutation. She was given warfarin and had several ischemic attacks in different vascular areas in the following years with various treatment strategies. MR angiography showed reversible stenosis of both internal carotid arteries (ICA) in every attack with different severities. We diagnosed the patient as reversible vasoconstriction syndrome of the ICA and started prednisolone, nimodipine, and ASA treatment. In conclusion, spontaneous reversible extracranial internal carotid artery vasospasm is a rare condition with uncertain pathology. There is also no effective treatment.

Keywords: Reversible carotid spasm, recurrent stroke, internal carotid artery

INTRODUCTION

Reversible idiopathic extracranial ICA vasospasm is a rare cause of ischemic stroke especially seen in the young. It may be caused by mechanical manipulation, migrainous headache or ergotism.^{1,3} It is less common to occur spontaneously which is described in only a few cases. The pathophysiology of the spontaneous cases is not well understood. There is hypothesis such as lack of parasympathetic innervation in the extracranial ICA or hypersensitivity of ICA's to neuropeptide Y and noradrenaline.^{4,5} Here we present a case of recurrent ischemic stroke due to spontaneous reversible extracranial ICA vasospasm (SREICAV) in a young female.

CASE REPORT

A 23-year-old female patient was admitted to our hospital with left hemiparesis and hemihypoesthesia in 2015. She had 5-6 hypoesthesia attacks on her left arm in the last 2

years which lasted for 30 minutes, but she was not admitted to the hospital. She had migraine-type headaches 4-5 times a month. She also had a bipolar disease and was using aripiprazole 2.5 mg/day. In the neurological examination, she had left-sided grade 4/5 muscle weakness and left hemihypoesthesia. Magnetic resonance imaging (MRI) showed multiple infarction on the right middle cerebral artery (MCA) territory. MR angiography (MRA) of extra and intracranial vessels showed no abnormality (Figure 1). She had no history of drug or any medicine abuse and urine toxicology tests were negative. Her transthoracic and transesophageal echocardiography was normal. Complete blood count and routine biochemical parameters were normal. Anti-ds DNA, anti-nuclear antibody, anti-cardiolipin antibody, anti-phospholipid antibody, anti-ro antibody, anti-la antibody homocysteine, fibrinogen, factor V, prothrombin, factor 12, PAI-1, MTHFR tests were performed and except PAI-1 heterozygote 4G/5G mutation, all were normal.

Address correspondence to: Dr. Zeynep Özdemir, Neurology Department, Bakirkoy Prof. Dr. Mazhar Osman Education and Research Hospital for Psychiatric and Neurological Diseases, Istanbul, Turkey. Tel: +90 5372816513, Email: zynp.ozdemir@hotmail.com

Date of Submission: 14 October 2021; Date of Acceptance: 5 November 2021

<https://doi.org/10.54029/2022vmm>

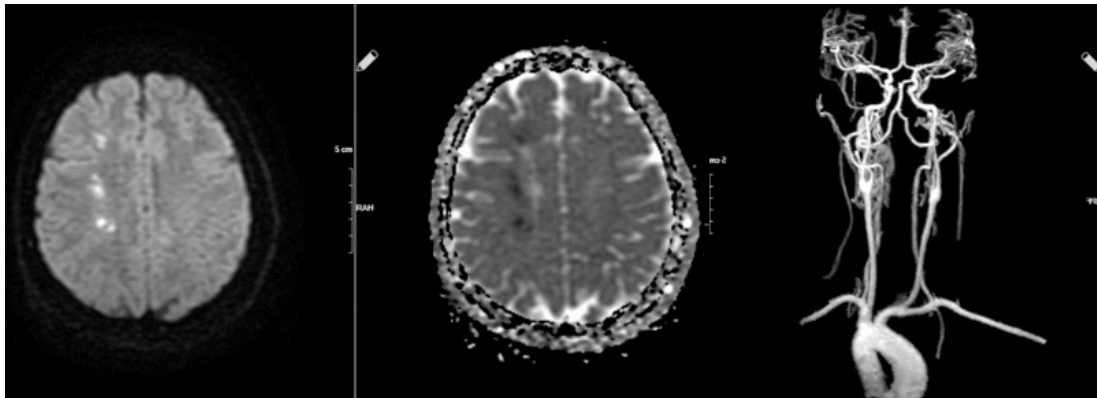


Figure 1. Patient's first ischemic episode with multiple right MCA infarct and normal MR angiography

We started warfarin based on a possible cardiac emboli etiology. She was discharged with no sequelae.

During follow up, we repeated cardiological and hematological tests which were all normal. We decided to stop the warfarin and started acetylsalicylic acid (ASA) 100 mg/day. Six months later she had a right-sided hemiparesis attack and we found border zone infarction areas between the left middle cerebral artery (MCA) and anterior cerebral artery (ACA) territory. MRA showed 90% stenosis on the left and 50% stenosis on the right internal carotid artery (ICA) (Figure 2). We started clopidogrel 75 mg/day plus warfarin. She was discharged with planned digital subtraction angiography (DSA) which was performed 4 months later which showed no stenosis.

One year after the last attack, she had another episode of left-sided hemiparesis, but we did not find any infarction on MRI. MRA showed critical stenosis on right ICA. ASA 100 mg/day was added to her treatment. One month later, she had a fourth attack while taking warfarin,

clopidogrel, and ASA. MRI showed no infarction and left ICA occlusion (Figure 3). After 3rd day of hospitalization, MRA showed no stenosis. When we further explored the history, we learned that some attacks occurred during menstruation and after sleeping. We thought she might have hemiplegic migraine. We started acetazolamide 250 mg/day and stopped the ASA. We performed an electroencephalography (EEG) and found excessive slowing in the right frontocentral region on the same side as the stroke. We consulted with the rheumatology department for possible vasculitic aetiology. They started methotrexate 15 mg/week based on possible Takayasu arteritis. She had further right MCA territory transient ischemic attacks with right ICA stenosis (Figure 4).

Brain and leptomeningeal biopsy was performed for differential diagnosis of central nervous system vasculitis and the histopathology was normal. We diagnosed the patient as reversible vasoconstriction syndrome of ICA, stopped methotrexate and warfarin and started 8 mg/day prednisolone and 240 mg/day nimodipine and ASA. We could not completely control these

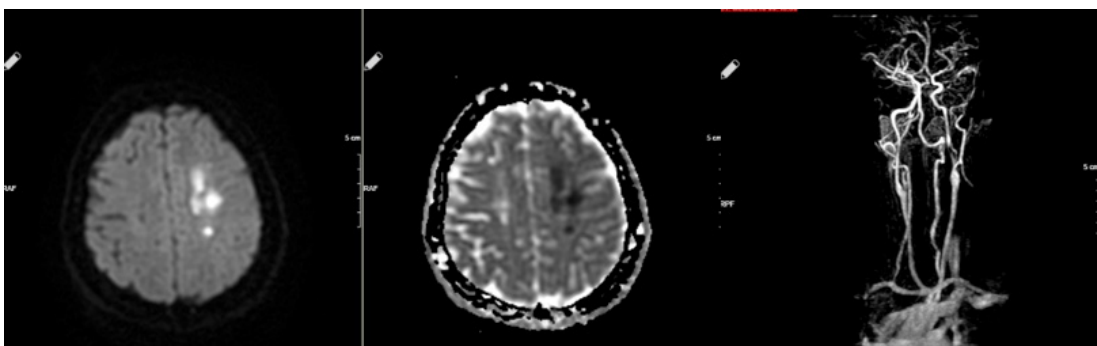


Figure 2. Left side acute ischemic stroke and MR angiography; 90% stenosis on the left and 50% stenosis on the right ICA

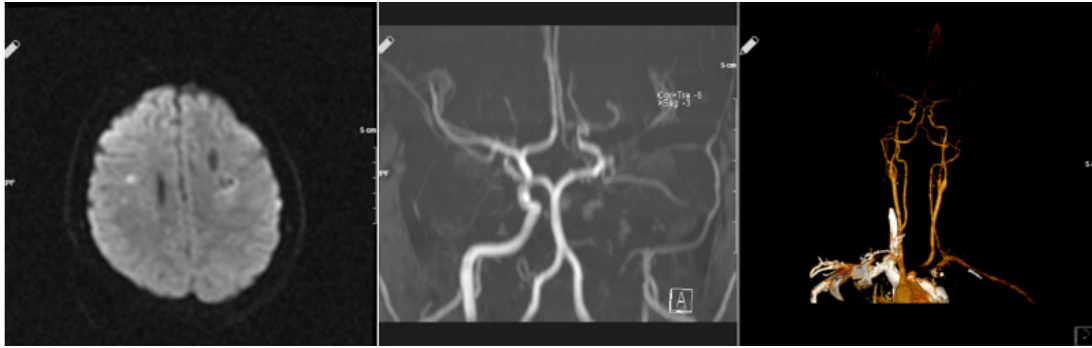


Figure 3. Left: Brain MRI DWI showed no infarction on the left side. Middle: Left ICA occlusion. Right: 10 days later, CT angiography shows normal left ICA.

attacks with this treatment and she decided to use only ASA for stroke and flunarizine for migraine.

DISCUSSION

Reversible cerebral vasoconstriction syndrome has multiple defined pathology as compared to SREICAV. One possible pathophysiological theory of SREICAV is endothelial dysfunction in the cerebral circulation which may differ from systemic endothelial function.⁶ Vasospasm of the extracranial ICA may be secondary to trauma, drugs such as ergot, illicit drugs or angiographic procedures.^{1,7} The condition often present with thunderclap or migrainous headache with or without neurological deficits. Liebermann *et al.* described a patient with a history of migraine and showed reversible vasospasm of both intracranial and extracranial cerebral arteries on angiogram.⁸ While cerebral vasospasms are more closely associated with migrainous headaches, it is unclear whether SREICAV is related to migrainous headaches or whether headaches are always part of these episodes. However, similar reversible angiographic observations which were called 'idiopathic regressing arteriopathy' have been reported in three patients without a

history of migraine.⁹ We could not attribute the attacks of our case to migraine because some of the ischemic attacks were not simultaneously associated with headache and her headache attacks were successfully treated with migraine treatment. Based on mechanisms involved in the pathophysiology of migraine, ergot-derived drugs or vasoactive substances can cause cerebral vasoconstriction syndrome, but autonomic innervation of intracranial vessels and extracranial vessels are different.^{1,10} Overactivity of sympathetic nervous innervation of the ICA which originates from superior cervical ganglion may be a possible cause of these vasospasms but the trigger mechanism is still unclear. Based on sympathetic nervous overactivity theory, Yokoyama *et al.* performed stellate ganglion blockage to their patient and reported benefit from this treatment, that temporarily ceased the carotid spasms.

It is known that some illicit drugs such as methamphetamine or cannabis have been linked to usually intracerebral, rarely extracerebral vasospasms but our patient's urine toxicology tests were negative.^{11,12} Another differential diagnosis is a stylo-carotid syndrome named

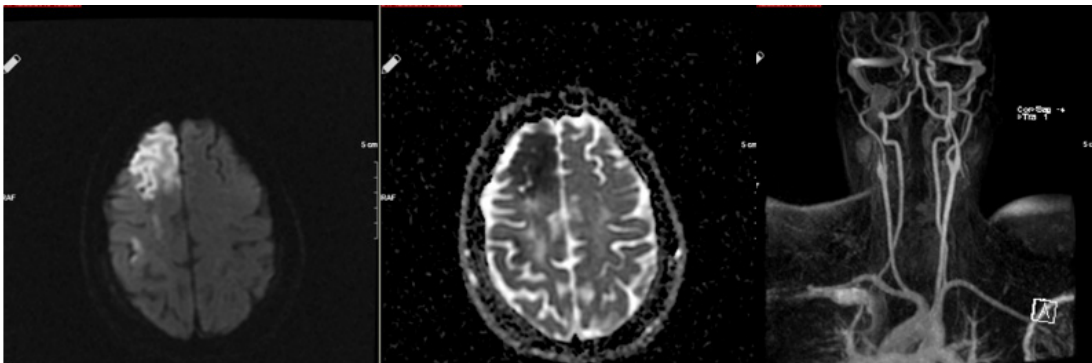


Figure 4. Right side acute ischemic stroke and MR angiography showing occlusion of the right ICA

as the second form of Eagle syndrome. In this syndrome, internal or external carotid artery compresses by elongated (usually >3 cm) styloid process and patients are presented with carotidynia, cervicofacial pain which can mimic cluster headache/migraine caused by irritation of the periarterial sympathetic nerve plexus or transient ischemic attacks provoked by head turning.¹³ We measured our patient's styloid process with 3D CT as 2,7 cm on the right and 3,1 cm on the left. During the DSA process, we turned and flexed our patient's neck and did not see any mechanical compression on ICA. We thought that mild contact of the styloid process to the ICA may irritate the sympathetic nerves in the arterial sheath, but the styloid process was not elongated enough to make significant stenosis on the ICA. Thus, we did not consider a surgery for the styloid process in our patient. There are some other possible mechanisms like a heterozygous mutation in the ACOX3 gene, reduced nitric oxide (NO) production associated with endothelial nitric oxide synthase (eNOS) T-786C polymorphism, or increased 20-hydroxyeicosatetraenoic acid (20-HETE), which may cause vasoconstriction.¹⁴⁻¹⁶

Clinical symptoms depend on the side of the spasm vessel and occlusion duration. Unilateral visual impairment can occur if the spasm extends to the ophthalmic and retinal arteries, with ipsilateral headache, contralateral hemiparesis, numbness and sensory impairment.^{17,18} Based on these pathogenic mechanisms, it is thought that vasodilators such as nitrate or calcium channel blockers may play a role in the treatment.

Unfortunately, the pathomechanism of SREICAV is still unclear, consequently, there is no standardized treatment. Based on reported literature; the youngest patient was 13 years old and it is mostly seen in the 3rd decade, and there is no gender predisposition.^{10,19} In the retrospective review by Biller *et al.* based on 24 cases, there is no consensus on the optimal treatment and stenosis recurred despite combined treatments in many cases as in our patient.¹⁰ Our patient had ischemic stroke under combined dual antiplatelet and anticoagulant therapy, although we could partially control the frequency of these attacks with vasodilatory treatment. This suggests that sympathetic blockade may play a role in treatment.

Some authors have suggested that the vasospasm may be induced by local inflammatory reaction and corticosteroids would suppress this hyperreactivity.²⁰ Similarly, some cases have benefited from oral steroids while others had recurrence under steroid treatment. Our patient

was given steroid with provisional diagnosis of Takayasu's arteritis, the steroid she did not prevent these attacks.^{3,7} Therefore, it is difficult to conclude that SREICAV is an autoimmune disease.

Carotid artery stenting or balloon angioplasty are other treatment choices.^{21,22} Clinical benefits have been reported but did not prevent recurrence in some cases.¹⁴ If the vasospasms were seen on the same side and segment each time, as in the case of Arning *et al.*, it may benefit from stenting.²³ After consultation with interventional neuroradiologists, we decided not to proceed with stent placement at the carotid bifurcation, as it could not prevent spasm of the other segments of ICA.

SREICAV is extremely rare but some cases may be misdiagnosed as arterial dissection or hemiplegic migraine if neurovascular imaging is not performed. It also can be diagnosed with immediate and serial vessel imaging, hence, the condition may be underestimated.²⁴ There is no long-term effective treatment since all data about SREICAV is retrospective. We need further studies to determine the pathophysiology of the syndrome and its effective treatment.

DISCLOSURE

Financial Support: None

Conflict of interest: None

REFERENCES

1. Mawet J, Debette S, Boussier MG, Ducros A. The link between migraine, reversible cerebral vasoconstriction syndrome and cervical artery dissection. *Headache* 2016;645-56. Doi: 10.1111/head.12798.
2. Solomon S, Lipton RB, Harris PY. Arterial stenosis in migraine: Spasm or arteriopathy? *Headache J Head Face Pain* 1990;30(2):52-61. Doi: 10.1111/j.1526-4610.1990.hed3002052.x.
3. Huisa BN, Roy G. Spontaneous cervical internal carotid artery vasospasm: Case report and literature review. *Neurol Clin Pract* 2014; 4(5): 461-4. doi: 10.1212/CPJ.0000000000000067
4. Moeller S, Hilz MJ, Blinzler C, *et al.* Extracranial internal carotid artery vasospasm due to sympathetic dysfunction. *Neurology* 2012;78(23):1892-4. Doi: 10.1212/WNL.0b013e318258f7ab.
5. Yokoyama H, Yoneda M, Abe M, *et al.* Internal carotid artery vasospasm syndrome: Demonstration by neuroimaging. *J Neurol Neurosurg Psychiatry* 2006;888-9. Doi: 10.1136/jnnp.2005.079798.
6. Choi HA, Lee MJ, Chung CS. Cerebral endothelial dysfunction in reversible cerebral vasoconstriction syndrome: a case-control study. *J Headache Pain*

- 2017;18(1):29. Doi: 10.1186/s10194-017-0738-x.
7. Janzarik WG, Ringleb PA, Reinhard M, Rauer S. Recurrent extracranial carotid artery vasospasms: Report of 2 cases. *Stroke* 2006;37(8):2170-3. Doi: 10.1161/01.STR.0000231646.30541.d8.
8. Lieberman AN, Jonas S, Hass WK, *et al.* Bilateral cervical carotid and intracranial vasospasm causing cerebral ischemia in a migrainous patient: A case of "diplegic migraine" . *Headache* 1984;24(5):245-8. doi: 10.1111/j.1526-4610.1984.hed2405245.x.
9. Mokri B, Houser OW, Sundt TM. Idiopathic regressing arteriopathy. *Ann Neurol* 1977; 2(6): 466-72. doi.org/10.1002/ana.410020605.
10. Graham E, Orjuela K, Poisson S, Biller J. Treatment challenges in idiopathic extracranial ICA vasospasm case report and review of the literature. *ENeurologicalSci* 2021;22:100304. Doi: 10.1016/j.ensci.2020.100304.
11. Jung JS, Park YW, Lee SA, Song TJ, Lim SM. Ischemic stroke after use of cannabis: A case report and review of literature. *Investig Magn Reson Imaging* 2018;22(3):168. Doi: 10.13104/IMRI.2018.22.3.168.
12. P V, M P, P R. Recurrent extracranial internal carotid artery vasospasm associated with recreational marijuana use. *Clin Imaging* 2017;43:6-8. Doi: 10.1016/J.CLINIMAG.2016.12.010.
13. Dao A, Karnezis S, Lane JS, Fujitani RM, Saremi F. Eagle syndrome presenting with external carotid artery pseudoaneurysm. *Emerg Radiol* 2011;18(3):263–5. Doi: 10.1007/s10140-010-0930-7.
14. Kim JT, Won SY, Kang KW, *et al.* ACOX3 Dysfunction as a Potential Cause of Recurrent Spontaneous Vasospasm of Internal Carotid Artery. *Transl Stroke Res* 2020;11(5):1041-51. Doi: 10.1007/s12975-020-00779-z.
15. Glueck CJ, Valdes A, Bowe D, Munsif S, Wang P. The endothelial nitric oxide synthase T-786c mutation, a treatable etiology of Prinzmetal's angina. *Transl Res* 2013;162(1):64-6. Doi: 10.1016/j.trsl.2013.03.003.
16. Mulligan SJ, MacVicar BA. Calcium transients in astrocyte endfeet cause cerebrovascular constrictions. *Nature* 2004;431(7005):195-9. Doi: 10.1038/nature02827.
17. Dembo T, Tanahashi N. Recurring extracranial internal carotid artery vasospasm detected by intravascular ultrasound. *Intern Med* 2012;51(10):1249–53. Doi: 10.2169/INTERNALMEDICINE.51.7066.
18. Mosso M, Jung HH, Baumgartner RW. Recurrent spontaneous vasospasm of cervical carotid, ophthalmic and retinal arteries causing repeated retinal infarcts: a case report. *Cerebrovasc Dis* 2007;24(4):381-4. Doi: 10.1159/000107919.
19. Fujii Y, Hanaoka Y, Ogiwara T, Koyama JI, Horiuchi T. Pediatric case of life-threatening stroke caused by reversible cerebral vasoconstriction syndrome with spontaneous cervical internal carotid artery vasospasm: A case report. *J Stroke Cerebrovasc Dis* 2021;30(10):106036. Doi: 10.1016/J.JSTROKECEREBROVASDIS.2021.106036.
20. Takeuchi M, Saito K, Kajimoto K, Nagatsuka K. Successful corticosteroid treatment of refractory spontaneous vasoconstriction of extracranial internal carotid and coronary arteries. *Neurologist* 2016;21(4):55-7. Doi: 10.1097/NRL.0000000000000080.
21. Levecque E, Goffette P, Duprez T, Peeters A. Idiopathic internal carotid artery vasospasm successfully treated with balloon angioplasty. *Acta Neurol Belgica* 2020 1206 2020;120(6):1477-9. Doi: 10.1007/S13760-020-01427-X.
22. Takahira K, Kataoka T, Ogino T, *et al.* Treatment of Idiopathic Recurrent Internal Carotid Artery Vasospasms with Bilateral Carotid Artery Stenting: A Case Report. *J Neuroendovascular Ther* 2017;11(5):246-52. Doi: 10.5797/JNET.CR.2016-0053.
23. Arning C, Schrattenholzer A, Lachenmayer L. Cervical carotid artery vasospasms causing cerebral ischemia. *Stroke* 1998;29(5):1063-6. Doi: 10.1161/01.STR.29.5.1063.
24. Wöpping S, Kastrup A, Lentschig M, Brunner F. Recurrent strokes due to transient vasospasms of the extracranial internal carotid artery. *Case Rep Neurol* 2013;5(2):143-8. Doi: 10.1159/000354827.