

## CASE REPORTS

# Ramsay Hunt syndrome presenting with abducens nerve palsy followed by V, VII, VIII, IX, and X nerve palsies

<sup>1</sup>Shi-Lin Yang MD, <sup>2</sup>Jun-Fang Zhang MD, <sup>2</sup>Li Zhang MD, <sup>2</sup>Ming Zhu MD

<sup>1</sup>Department of Neurology, Huashan Hospital, Fudan University; <sup>2</sup>Department of Neurology, Shanghai General Hospital, Shanghai Jiao Tong University School of Medicine, Shanghai, China

### Abstract

Ramsay Hunt syndrome, associated with varicella zoster virus infection is characterized by herpes zoster oticus, facial nerve palsy, and cochleovestibular symptoms. Ramsay Hunt syndrome associated cranial polyneuropathy occasionally occurs with involvement beyond VII and VIII. We represent a patient of Ramsay Hunt syndrome who presented with only VI involvement at the first visit followed by cranial polyneuropathy. Varicella zoster virus infection was confirmed by the detection of varicella zoster virus-DNA in cerebrospinal fluid.

**Keywords:** Ramsay Hunt syndrome; varicella zoster virus; cranial polyneuropathy; abducens nerve palsy

### INTRODUCTION

Ramsay Hunt syndrome (RHS), first described by J. Ramsay Hunt in 1907 is characterized by herpes zoster oticus, peripheral facial nerve palsy, and cochleovestibular symptoms associated with reactivation of varicella zoster virus (VZV) in geniculate ganglion.<sup>1</sup> Cranial nerves beyond VII and VIII are involved in 1.8% of RHS cases, which can lead to dysphagia, dysarthria and other symptoms.<sup>2</sup> Involvement of VI nerve is extremely rare.<sup>3,4</sup> We report a patient of RHS who presented with only VI nerve involvement at the first visit, and subsequently developed ipsilateral cranial polyneuropathy.

### CASE REPORT

A 63-year-old man presented to the emergency department, complaining of a 6-day history of right sided tingling headache, otalgia and pharyngalgia, and a 4-day history of diplopia, dizziness and vomiting. The patient has past history of rheumatoid arthritis, well controlled with methotrexate and leflunomide. On examination, the vital signs were normal. Right sided complete abducens nerve palsy was observed (Figure 1, A). Other cranial nerves were normal. Crusting, pus and debris in the right external auditory canal were noted (Figure 1, B). The hematological

investigation revealed normal leukocytes count of  $4.88 \times 10^9/L$ , with an elevated monocyte of 12.7% (normal range: 3%-10%), suggesting a virus infection. Head CT demonstrated only nonspecific ischemic lesions. He refused hospitalization and went home, after oral acyclovir, prednisone (30mg/d) and mecobalamin were prescribed.

After 8 days, he came back complaining of right sided facial droop and hearing impairment that developed 4 days earlier. He denied visual loss, dysphagia, hoarseness of voice, tinnitus and unsteadiness. Neurological examination showed right peripheral facial palsy (Figure 1, C) and right facial hypoesthesia. The soft palate drooped on the right side, uvula deviating towards left (Figure 1 D), and the gag reflex was absent on the right side. He showed right sided hearing loss, with a positive Rinne test (air conduction longer than bone conduction) bilaterally and a Weber test lateralizing to left, suggestive of right sensorineural hearing loss. This was confirmed later by pure tone audiometry demonstrating increased both air and bone conduction thresholds at high frequencies without an air-bone gap on the right ear (Figure 2).

Laboratory investigations revealed increased erythrocyte sedimentation rate (ESR) of 35mm/h (normal range: 0-15mm/h) but normal C reactive protein of 3.9mg/L (normal range: 0-10mg/L).

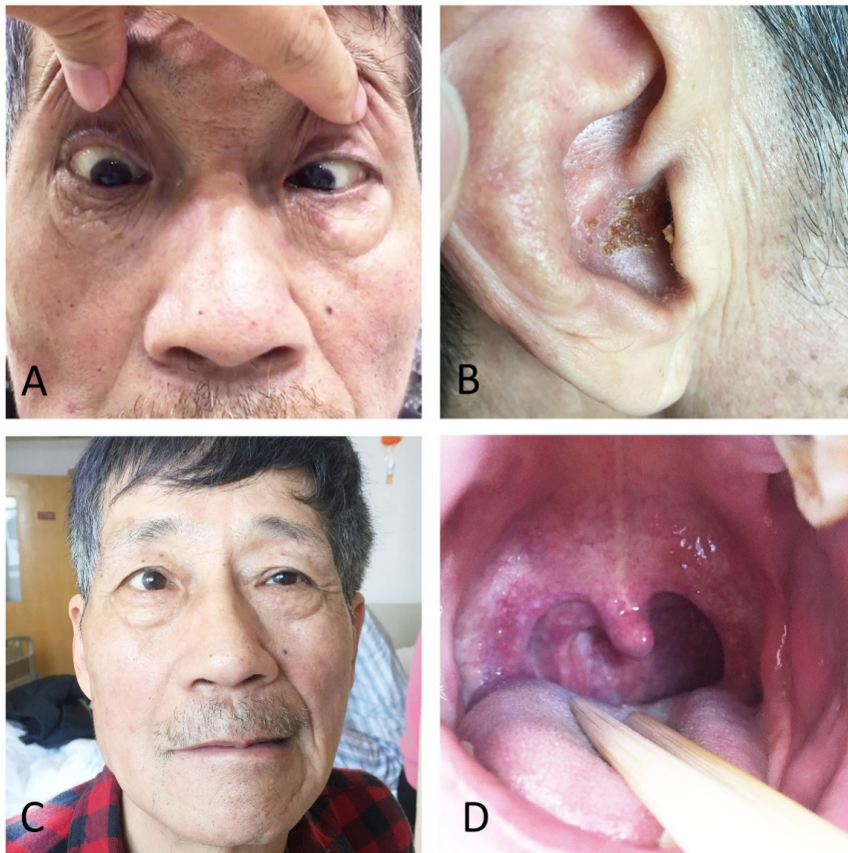


Figure1. (A) Patient showing right sided complete abducens palsy, wherein the right eye failed to abduct when he was asked to look to the right side. (B) Crusting, pus and debris in the right external auditory canal were seen. (C) Showing right peripheral facial palsy. (D) showing the soft palate drooped on the right side, and uvula deviated towards left.

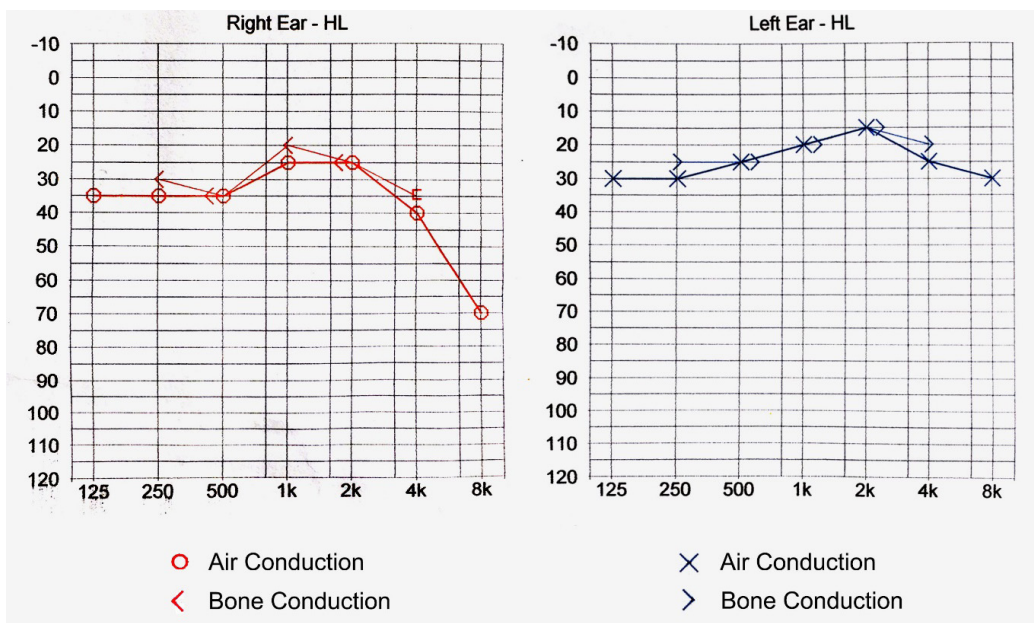


Figure2. Pure tone audiometry demonstrated increased both air and bone conduction thresholds at high frequencies without an air-bone gap on the right ear, confirming right sensorineural hearing loss.

Complete blood count showed normal leukocytes count of  $5.30 \times 10^9/L$ , however with an elevated neutrophils of 75.6% (normal range: 50%-70%). Renal and liver function tests were normal. Lumbar puncture revealed an opening pressure of 50mm H<sub>2</sub>O, mildly elevated protein level of 0.61g/L (normal range: 0.15-0.5g/L), normal glucose level of 3.51mmol/L, and pleocytosis of  $43 \times 10^6/L$  (normal range:  $0-8 \times 10^6/L$ ), with 90% monocyte. Polymerase chain reaction (PCR) of the cerebrospinal fluid (CSF) was positive for VZV-DNA, and negative for herpes simplex virus (HSV)-DNA, cytomegalovirus (CMV)-DNA and Japanese encephalitis virus (JEV)-RNA. Magnetic resonance imaging did not show any significant abnormalities in the brain stem or cranial nerves before and after gadolinium injection.

Ganciclovir (375mg) was administered intravenously once every 12 hours for 2 weeks. Methylprednisolone (500mg/d) was given intravenously for 3 days followed by a tapering schedule that lasted one month. Gabapentin was used to control his headache, otalgia and pharyngalgia. One month after onset of illness, his hearing improved clinically; 2 months after onset of illness, he had minimally limited abduction of right eye and mild right facial palsy.

## DISCUSSION

RHS is a well-known group of manifestations caused by VZV reactivation in the geniculate ganglion.<sup>1</sup> It presents with the classic triad of herpes of the auricle and external auditory canal, paralysis of the facial nerve, and cochleovestibular symptoms.<sup>1</sup> Occasionally it can be accompanied by involvement of other cranial nerves.<sup>3-17</sup> It was reported that the most commonly involved cranial nerves were VII, VIII, IX, X, V and III/ XII in descending order in a study of 11 cases.<sup>2</sup> A review of literature by Aviel and Marshak revealed that VII, VIII, IX, V, X and VI could be involved in order of decreasing frequency.<sup>5</sup> Involvement of VI was rarely reported in RHS.<sup>2,4</sup> Our patient presented with VI nerve palsy alone initially, and then developed dysfunction of other cranial nerves (including V, VII, VIII, IX, and X). Absence of VII and VIII nerve palsies in the early stage of the disease in our case made the early diagnosis of RHS challenging. Fortunately, the patient showed signs of vesicular rashes in the external auditory canal in the early stage, giving important clue to the underlying etiology of VZV infection. RHS without herpes oticus has been reported.<sup>17</sup> Thus, the differential diagnoses of isolated abducens nerve palsy should include

RHS, even when vesicular rashes are not found.

Latent VZV in cranial nerve ganglia can reactivate and replicate when host immunity becomes compromised.<sup>18</sup> Long term use of immunosuppressants (methotrexate and leflunomide) for rheumatoid arthritis might be a precipitating factor in the present case. The exact mechanism of cranial polyneuropathy associated with VZV infection remains unclear. J. Ramsay Hunt proposed that the associated inflammation extends from the geniculate ganglion to adjacent nerves or simultaneously involves other ganglia.<sup>19</sup>

RHS associated with cranial polyneuropathy has a good prognosis for cranial nerve palsies when treated with a combination therapy of antiviral agents and steroids, but not for recovery of hearing loss.<sup>2</sup> Early treatment of RHS is said to be associated with a better outcome.<sup>20</sup> In one study, complete recovery of facial paralysis was achieved in 75% of RHS patients who were treated (acyclovir and prednisolone) within the first 3 days, compared with only 30% of those in whom treatment began more than 7 days after onset. Hearing recovery also tended to be better in patients with early treatment.<sup>20</sup> We initiated combined treatment of antiviral drugs and steroids at the patient's first visit when the VZV infection was suspected clinically, and the patient achieved a good outcome. Although detection of VZV-DNA by PCR can aid the diagnosis of RHS, it should not delay early treatment since early initiation of combination therapy improves the outcome.

## DISCLOSURE

Conflict of interest: None

## REFERENCES

1. Hunt J. On herpetic inflammation of geniculate ganglion. A new syndrome and its complications. *J Nerve Ment Dis* 1907;34:73-97.
2. Kim YH, Chang MY, Jung HH, et al. Prognosis of Ramsay Hunt syndrome presenting as cranial polyneuropathy. *Laryngoscope* 2010;120(11):2270-6.
3. Kim CH, Kang SI, Kim YH. A case of ramsay hunt syndrome with cranial polyneuropathy. *Korean J Audiol* 2012;16(2):80-2.
4. Nagano K, Yoshimura K, Yamasaki M. A case of Ramsay Hunt syndrome associated with local meningitis, multiple cranial neuropathy, and the second cervical nerve involvement. *Rinsho Shinkeigaku* 1999;39(4):475-7.
5. Aviel A, Marshak G. Ramsay Hunt syndrome: a cranial polyneuropathy. *Am J Otolaryngol* 1982;3(1):61-6.
6. Asnis DS, Micic L, Giaccio D. Ramsay Hunt syndrome presenting as a cranial polyneuropathy. *Cutis* 1996;57(6):421-4.

7. Turner JE, Geunes PM, Schuman NJ. Cranial polyneuropathy--Ramsay Hunt's syndrome: case report and discussion. *Oral Surg Oral Med Oral Path Oral Radiol Endod* 1997;83(3):354-7.
8. De S, Pfeleiderer AG. An extreme and unusual variant of Ramsay Hunt syndrome. *J Laryngol Otol* 1999;113(7):670-1.
9. Xanthopoulos J, Noussios G, Papaioannides D, *et al.* Ramsay Hunt syndrome presenting as a cranial polyneuropathy. *Acta Otorhinolaryngol Belg* 2002;56(3):319-23.
10. Padhiary KN, Mishra A, Routray P. Ramsay Hunt syndrome presenting as cranial polyneuropathy. *J Assoc Physicians India* 2007;55:308-9.
11. Sugita-Kitajima A, Sato S, Koizuka I. Ramsay Hunt syndrome with cranial polyneuropathy involving cranial nerves VII, VIII, IX, and X. *Nihon Jibiinkoka Gakkai Kaiho* 2009;112(9):656-9.
12. Sun WL, Yan JL, Chen LL. Ramsay Hunt syndrome with unilateral polyneuropathy involving cranial nerves V, VII, VIII, and XII in a diabetic patient. *Quintessence Int* 2011;42(10):873-7.
13. Lee DH, Yoon TM, Lee JK, *et al.* Herpes zoster laryngitis accompanied by Ramsay Hunt syndrome. *J Craniofac Surg* 2013;24(5):e496-8.
14. Shinha T, Krishna P. Ramsay Hunt syndrome and zoster laryngitis with multiple cranial nerve involvement. *ID Cases* 2015;2(2):47-8.
15. Gunbey HP, Kutlar G, Aslan K, *et al.* Magnetic resonance imaging evidence of varicella zoster virus polyneuropathy: Involvement of the glossopharyngeal and vagus nerves associated with Ramsay Hunt syndrome. *J Craniofac Surg* 2016;27(3):721-3.
16. Steele L, Ghedia R, Ahmad H, *et al.* Ramsay Hunt syndrome with cranial polyneuropathy with features of supraglottitis. *BMJ Case Rep* 2017;2017.
17. Tecellioglu M, Kamisli S, Erbay MF, *et al.* A rare presentation of cranial polyneuropathy without rash caused by varicella zoster virus. *Med Arch* 2017;71(4):293-5.
18. Mueller NH, Gilden DH, Cohrs RJ, *et al.* Varicella zoster virus infection: clinical features, molecular pathogenesis of disease, and latency. *Neurol Clin* 2008;26(3):675-97, viii.
19. Hunt J. The symptom-complex of the acute posterior poliomyelitis of the geniculate, auditory, glossopharyngeal and pneumogastric ganglia. *Arch Int Med* 1910;V(6):631-75.
20. Murakami S, Hato N, Horiuchi J, *et al.* Treatment of Ramsay Hunt syndrome with acyclovir-prednisone: significance of early diagnosis and treatment. *Ann Neurol* 1997;41(3):353-7.