

Spontaneous remission without progression to limbic encephalitis in a patient with LGI1 seropositive faciobrachial dystonic seizure

Sherrini Bazir Ahmad, Suhailah Abdullah, Chong Tin Tan, Kheng Seang Lim, Khean Jin Goh

Division of Neurology, Faculty of Medicine, University of Malaya, Kuala Lumpur, Malaysia

Abstract

Faciobrachial dystonic seizures are pathognomonic of leucine-rich glioma inactivated-1 (LGI1) antibody, non-paraneoplastic limbic encephalitis. Faciobrachial dystonic seizures usually precede limbic encephalitis by about a month. It is unknown whether, if untreated, faciobrachial dystonic seizures inevitably progress to limbic encephalitis. We present an LGI1 seropositive patient with a year's history of faciobrachial dystonic seizures, who achieved remission spontaneously without immunotherapy or antiepileptic drug treatment, and did not develop evidence of limbic encephalitis over a three-year follow-up.

INTRODUCTION

Antibodies against the voltage-gated potassium channel (VGKC) principally bind with leucine-rich glioma-inactivated protein 1 (LGI1) or with contactin associated protein-like2 (CASPR2) in the central and peripheral nervous systems.^{1,2} While these antibodies are characterized by amnesia, behavioural and psychiatric disturbances and hyponatraemia, CASPR2 antibodies are typically associated with peripheral motor excitability and Morvan syndrome² while LGI1 are more often associated with limbic encephalitis and epilepsy which may be drug resistant.¹⁻⁶

A stereotypical seizure associated with LGI1 antibodies is the faciobrachial dystonic seizure (FBDS), which precedes the onset of limbic encephalitis by about a month.³ These seizures are brief (< 3 seconds) with frequent dystonic posturing (up to > 50 times/day) almost always affecting the arm (unilateral or bilateral), frequently associated with ipsilateral facial grimacing and may involve the leg.³ They are almost always refractory to antiepileptic drugs (AEDs), but are responsive to immunotherapy. In a series of 29 patients with FBDS, 3 were treated with immunotherapy and did not progress to limbic encephalitis.³ The authors commented that it was not yet clear if untreated, FBDS would inevitably proceed to limbic encephalitis.^{3,7}

We describe a case of LGI1 seropositive FBDS, without cognitive impairment, who achieved

spontaneous remission without immunotherapy or AED treatment. Subsequent follow-up did not show any progression of the disease.

CASE REPORT

A 74-year-old retired ethnic Indian Malaysian man presented with frequent episodes of brief involuntary jerky movements of his right neck, shoulder, hand and foot in January 2013. There was no associated loss of consciousness or cognitive impairment. His past medical history included hypertension and mild chronic renal impairment.

Initial investigations including an EEG and MRI brain were normal. No treatment was initiated. However, his attacks worsened over the next 4 months, occurring up to 50 times a day, resulting in spilled drinks or dropped objects, interfering with his daily activities. Each cluster of seizures lasted up to 5-10 minutes, and occurred both in sleep and wakefulness. His family members also noted brief episodes of 'blank stares' associated with oral automatism. He subsequently presented to the Neurology clinic, University of Malaya Medical Centre in May 2013 for a second opinion. Neurological examination was unremarkable and no cognitive impairment was noted on clinical testing. A repeat MRI brain was normal. A repeat EEG showed intermittent bilateral anterior temporal slow waves, which at times appeared rhythmic (Figure 1). The same finding was seen in the repeat EEG in early 2014. The EEGs were

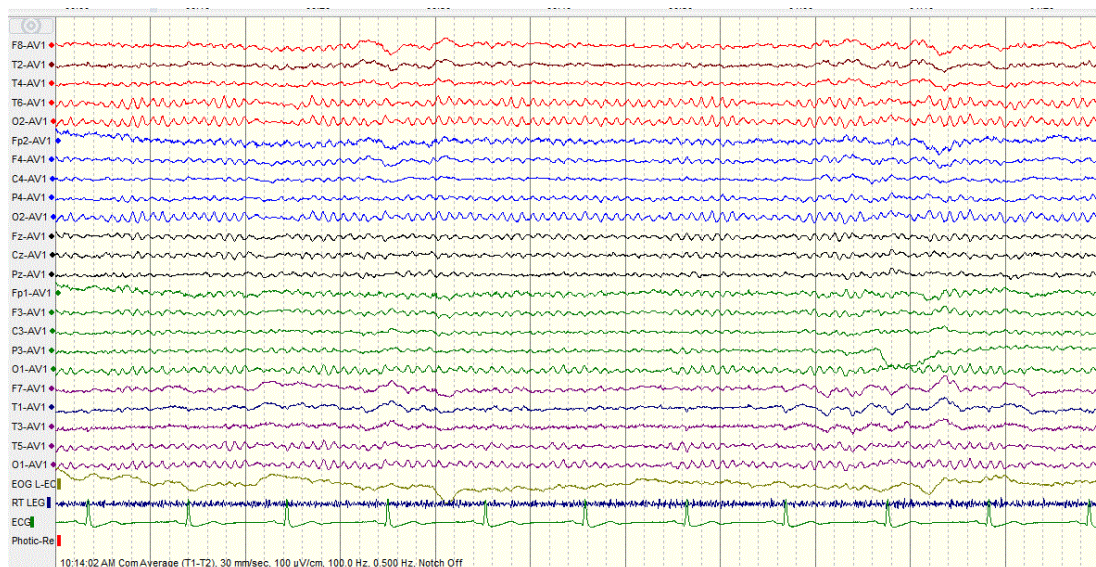


Figure 1. EEG done in May 2013 showing intermittent bilateral anterior temporal slow waves, with preserved posterior rhythm

thought to be within normal limit.

He was diagnosed with focal epilepsy and prescribed levetiracetam 250mg BD. However, he defaulted treatment after two weeks of taking the medication and only returned to our clinic for assessment 6 months later. At this point in time, he reported that his seizures had become less frequent, occurring only once a month despite not taking any medication. He denied any improvement in seizure frequency while on levetiracetam. By January 2014, his seizures had stopped and he remained seizure free till December 2015 without any further treatment.

His serum was subsequently found to be positive for LGI1 antibody but negative for CASPR2, using cell-based indirect immunofluorescence tests, confirming the diagnosis of FBDS due to anti LGI1 encephalitis. On follow up assessment, his neurological examination and cognitive function on mini mental state examination (MMSE) remained normal. However, the patient declined to undergo formal psychological assessment as he felt well. Serum sodium repeated twice was normal.

DISCUSSION

We described a case of LGI1 antibody positive FBDS, which spontaneously remitted 12 months after symptom onset, without AED or immunosuppressive therapy. He also did not manifest any cognitive impairment or other mental change to indicate progression to limbic

encephalitis over a follow up period of 3 years.

This report highlights the importance of being aware of this condition as our patient presented with typical FBDS, brief, frequent dystonic seizures, affecting the face and upper limb. In our patient, the diagnosis was considered only after two years. Probably due to the lack of response to AED (albeit treatment was taken for only 2 weeks) and the likelihood that the seizures did not significantly affect his daily activities (being retired from employment) caused him to initially default follow up.

The patient seizures subsequently remitted and he has not shown any clinical evidence of cognitive dysfunction. However, as we did not perform formal psychological assessment, it is possible that subtle cognitive impairment could have been missed.

Two adult cases of LGI1 limbic encephalitis were previously reported to show spontaneous remission without immunotherapy, although these patients had residual mild/moderate cognitive impairment after 3 to 5 years of follow up.⁸ Our case is further evidence that LGI1 encephalitis can occasionally have a relatively benign course with spontaneous remission without immunotherapy.

ACKNOWLEDGEMENT

We would like to thank the Institute for Medical Research, Kuala Lumpur for their laboratory assistance.

REFERENCES

1. Vincent A, Buckley C, Schott JM, *et al.* Potassium channel antibody associated encephalopathy: a potentially immunotherapy-responsive form of limbic encephalitis. *Brain* 2004; 127:701-12.
2. Klein CJ, Lennon VA, Aston PA, *et al.* Insights from LGI1 and CASPR2 potassium channel complex autoantibody subtyping. *JAMA Neurol* 2013; 70(2):229-34.
3. Irani SR, Michell AW, Lang B, *et al.* Faciobrachial Dystonic Seizures Precede Lgi1 Antibody Limbic Encephalitis. *Ann Neurol* 2011; 69:892-900.
4. Thieben MJ, Lennon VA, Boeve BF, *et al.* Potentially reversible autoimmune limbic encephalitis with neuronal potassium channel antibody. *Neurology* 2004; 62:1177-82.
5. Barajas RF, Collins DE, Chas S, *et al.* Adult-onset drug refractory seizure disorder associated with anti-voltage-gated potassium-channel antibody. *Epilepsia* 2009;51:473-7.
6. Lai M, Huijbers MG, Lancaster E, *et al.* Investigation of LGI1 as the antigen in limbic encephalitis previously attributed to potassium channels: a case series. *Lancet Neurol* 2010; 9:776-85.
7. Irani SR, Stagg CJ, Schott JM, *et al.* Faciobrachial dystonic seizures: the influence of immunotherapy on seizure control and prevention of cognitive impairment in a broadening phenotype. *Brain* 2013; 136(Pt 10):3151-62.
8. Szots M, Marton A, Kover F, *et al.* Natural course of LGI1 encephalitis: 3-5 years of follow-up without immunotherapy. *J Neurol Sci* 2014; 343(1-2):198-202.