

Diagnosis of X-Linked creatine transporter deficiency in a patient from Northeast China

¹Chun-Hui Hu, ¹Yu-Ying Fan, ¹Long-Fei Wang, ¹Tao Yu, ²Xiao-Ming Wang, ¹Hua Wang

¹Department of Pediatric Neurology & ²Department of Radiology, Shengjing Hospital, China Medical University, Shenyang, China

Abstract

Background: Creatine transporter (CRTR) deficiency is the most common creatine deficiency syndrome, of which the final diagnosis relies on mutation in the X-linked CRTR gene. To date, more than 90 mutations in the SLC6A8 gene have been reported. This paper discusses a novel mutation detected via the thorough sequencing of all the X-chromosome-specific exons investigated in a four and a half year old boy with an intellectual disability, speech and language delay and motor disturbance. **Methods:** A brain magnetic resonance imaging (MRI) and a proton magnetic resonance spectroscopy (MRS) were carried out, the creatine and creatinine concentrations in the urine were checked and all exons were sequenced. **Results:** A detailed clinical investigation revealed a reduction in the cerebral creatine levels in the brain by the MRS, elevated creatine and creatinine concentrations in the urine and signal abnormalities in the left frontal cortex of the brain by the MRI. A novel change was identified in the heterozygosity of the exon 10: c.1395-c.1401 deletion.

Conclusion: The use of a combination of powerful new technologies, such as thorough exome-next-generation sequencing and a brain MRS, should be considered, in order to determine any neurometabolic diseases, especially when the signal abnormalities in the brain MRI cannot be explained by any other factors. This mutation results most likely in a dysfunction of the creatine transport and synthesis, hence causing central nervous system symptoms.

INTRODUCTION

Creatine deficiency syndromes are confirmed congenital metabolic diseases of the creatine transport and synthesis, characterised by depleted cerebral creatine levels. The manifestations of the clinical symptoms are related, mainly, to intellectual disability (ID), speech and language retardation, autistic behaviour, epileptic seizures and hypomyotonia. It has been acknowledged that genetic defects play a significant role in these disorders. All these symptoms have been identified by either autosomal recessive, induced by mutations in the genes, encoding arginine glycine amid inotransferase (AGAT) (OMIM#612718) or guanidinoacetate methyltransferase (GAMT) (OMIM #612736), or they are X-linked, induced by mutations in the gene creatine transporter (CRTR) SLC6A8 (OMIM #300036, Gene ID: 6535). Oral creatine has been proved to be beneficial for individuals with AGAT or GAMT deficiency, and especially younger individuals, but not for those who experience CRTR deficiency.

CRTR deficiency is the most common cause of X-linked ID in males.^{1,2} The diagnosis of CRTR

deficiency depends on the clinical symptoms, biochemical metabolites, brain proton magnetic resonance spectroscopy (MRS) and gene mutation.³⁻⁵ The elevated creatine/creatinine ratio in the urine is helpful, and depleted cerebral creatine levels detected by the brain MRS are reliable, for a diagnosis, although the final diagnosis relies on the mutation in the X-linked CRTR gene.

The SLC6A8 gene consists of 13 coding exons, spanning approximately 8.3kb at Xq28. More than 90 mutations in this gene have been described. To date, approximately 120 patients have been diagnosed with CRTR deficiency.⁶ Not only have intragenic duplications involving exons been reported on, but RNA sequencing studies have also been conducted, in order to provide a better understanding of the clinical symptoms of CRTR deficiency.⁷

This paper reports on a novel SLC6A8 gene mutation discovered in a family, and which was detected via a deep sequencing of all the X-chromosome-specific exons.

CASE REPORT

The index patient was a four and a half year old boy, being a first-born child from a full term pregnancy and natural birth. The boy had ID, speech and language delay and motor disturbance. Both the pregnancy history and delivery of this boy were unremarkable. Although his mother experienced one seizure during the term of the pregnancy, her blood pressure monitoring results remained normal. The boy was able to raise his head at 4 months old and to sit up by the age of 8 months. However, when he was 13 months old, he was admitted to hospital after experiencing a seizure. The electroencephalogram recording was normal although the brain magnetic resonance imaging (MRI) showed callosal agenesis. However, a second brain MRI did not indicate any obvious deformities after the 13 months. He started walking at 3 years old. At four and a half years old he could only say “father” and “mother” and this general physical examination

at this age indicated a severe delay of language and testicular hydrocele. There were no other congenital abnormalities. Both the serum muscle enzymes and electromyography were within the normal values after serial determination. A third brain MRI revealed long T2 and high flair signals in the left frontal cortex of the brain (Figure 1).

Neuropsychological assessment

To evaluate the ID in this family, the Wechsler Intelligence Scale for Children Edition was applied for the boy, with the Wechsler Adult Intelligence Test Third Edition being employed for his parents. His father demonstrated a high IQ score of 90, while the score for his mother was 70. The boy was found to have a score of 35, which was the lowest in the family.

Genetic studies

The Genomic DNA was isolated from the blood

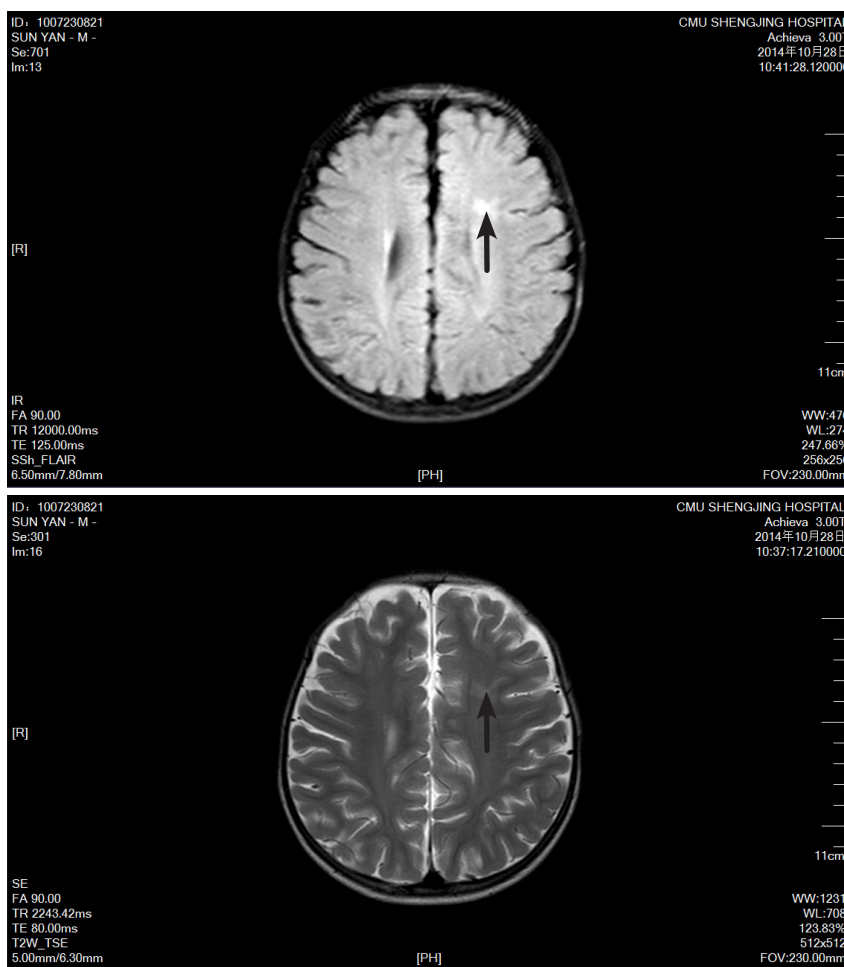


Figure 1. Brain magnetic resonance imaging of the boy at 4 and half years old

cells collected from the boy and his parents by the BloodGen Midi Kit (CWBIO, China), after firstly obtaining the parents' right of knowing and consent. All of the coding regions of the SLC6A8 gene were analysed by means of a thorough sequencing using an ABI 3730XL sequencing machine. The sequence analysis of the CRTR SLC6A8 identified a hemizygous 7bp deletion in the exon 10: c.1395-c.1401, at chrX: 152959831–152959837(1395-1401 del C T A C T C G). This new mutation has been depicted as being harmful, as the codon of the tyrosine TAC was replaced by the termination codon TAG at residue 465, resulting in the termination of protein synthesis. The boy's mother was found to be heterozygous for the mutation, although this mutation was not identified in his father (Figure 2).

Brain MRS

A brain MRS was performed at 3.0 T using a standard CP head coil. A marked reduction in the creatine levels in the brain MRS was confirmed (Figure 3).

Biochemical analysis

The mean values of the creatine and creatinine concentrations in the urine are 18651.81 $\mu\text{mol/L}$ and 4890.80 $\mu\text{mol/L}$, respectively. The creatine/creatinine ratio is 3813.65 mmol/mol (The normal range is 10–800 mmol/mol between 4 years and 15 years old)

DISCUSSION

In diagnosing a case of CRTR deficiency by means of a brain MRS and determining a creatine/creatinine ratio and X-linked CRTR gene in this study, a novel SLC6A8 gene mutation was discovered and a novel hemizygous 7bp deletion located in the exon 10 was detected. The mutation in which the codon of tyrosine TAC was replaced by the termination codon TAG at residue 465, resulting in the termination of protein synthesis, most likely induces the dysfunction of the creatine transport and synthesis. The heterozygous mutation was discovered in his mother, who has milder symptoms and suffered a seizure during her pregnancy. S. Dreha-Kulaczewski revealed that a male patient with hemizygous mutation in the SLC6A8 gene presented with the characteristic

of a severe phenotype comprising ID, as well as severe speech delay and behavioural disturbances, and all the heterozygous females portrayed milder symptoms. The male patients, therefore, with heterozygous mutation most probably suffered CRTR deficiency syndromes. There was no clear evidence of any correlation between the brain MRS, or the biochemical data, and the IQ scores of the heterozygous females with CRTR deficiency.

The symptoms of CRTR deficiency syndromes have been linked to intellectual disability, speech and language retardation, autistic behaviour and epileptic seizures. Muscle weakness and fatigue have been included in a minority of reports.^{8,9} In this study, no hypomyotonia or any other lipid storage myopathy were found.

A brain MRS can disclose creatine or other metabolites depletion indicating a reduced peak of total creatine in the spectrum. This study revealed a marked reduction in the creatine levels in the brain MRS. Currently, there are reports of quantitative brain MRS data of heterozygous females with CRTR deficiency, emphasising the importance of the quantitative brain MRS¹⁰. A third brain MRI highlighted long T2 and high flair signals in the left frontal cortex of the brain when he was four and half years old. To date, a reduction of the creatine signals in the brain MRS have been reported in almost all patients with CRTR deficiency, whilst few signal abnormalities in the brain MRI have been covered. In this case study, the signal abnormalities could not be explained by any other encephalopathy that may have been caused by reduced cerebral creatine levels. Regarding the patients with ID, severe speech and language delay and signal abnormalities in the brain MRI, this disease should also be considered, when the signal abnormalities in the brain MRI cannot be explained by any other factors.

In the patients with CRTR deficiency, the urinary creatine excretion relative to the creatinine excretion is elevated. The creatine/creatinine ratio can be used as an early diagnostic hallmark for this disease, which lays the emphasis of the next clinical examination.

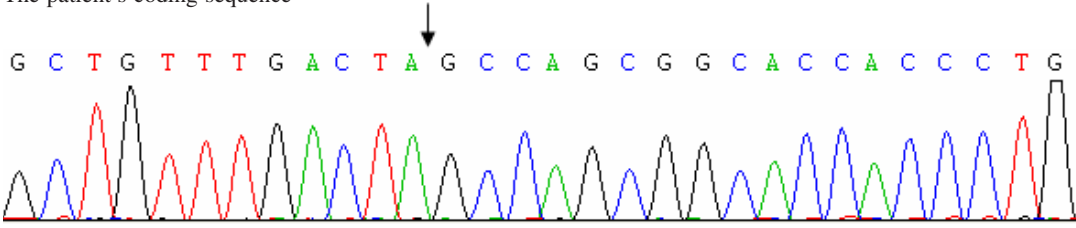
DISCLOSURE

Conflicts of interest: None

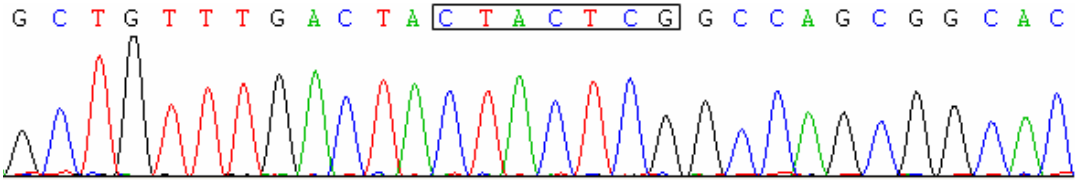
NCBI reference coding sequence

G C T G T T T G A C T A C T A C T C G G C C A G C G G C A C

The patient's coding sequence



The coding sequence of his father



The coding sequence of his mother

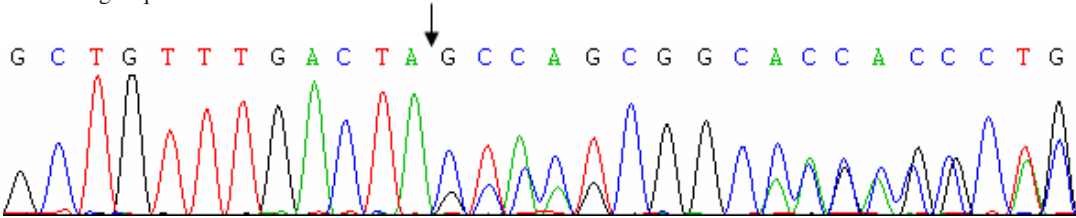


Figure 2. The coding sequence

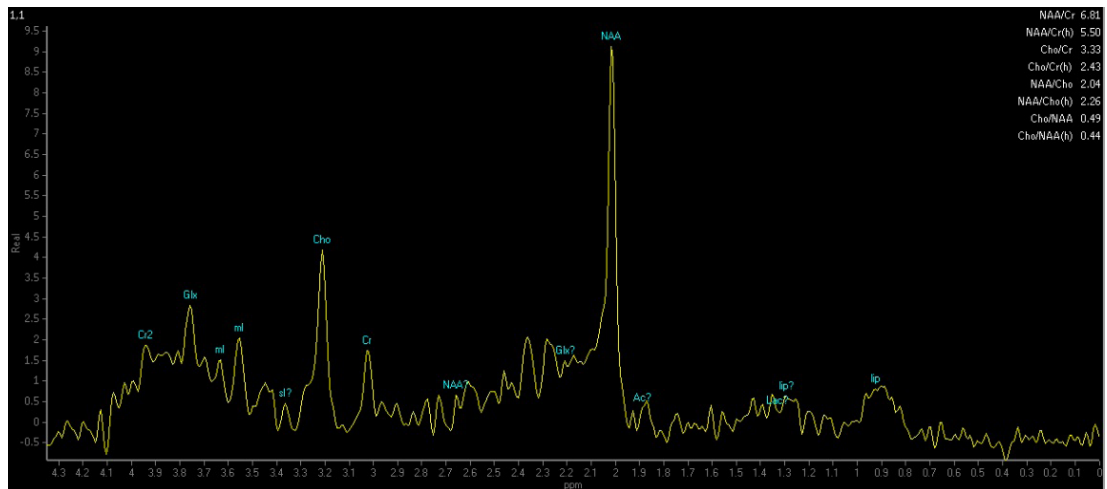


Figure 3. A marked reduction of the creatine levels in the brain MRS

REFERENCES

1. van de Kamp JM, Betsalel OT, Mercimek-Mahmutoglu S, *et al.* Phenotype and genotype in 101 males with X-linked creatine transporter deficiency. *J Med Genet* 2013; 50:463-72.
2. Stockler S, Schutz PW, Salomons GS. Cerebral creatine deficiency syndromes: clinical aspects, treatment and pathophysiology. *Subcell Biochem* 2007; 46:149-66.
3. Salomons GS, van Dooren SJ, Verhoeven NM, *et al.* X-linked creatine transporter defect: an overview. *J Inherit Metab Dis* 2003; 26:309-18.
4. Stromberger C, Bodamer OA, Stockler-Ipsiroglu S. Clinical characteristics and diagnostic clues in inborn errors of creatine metabolism. *J Inherit Metab Dis* 2003; 26:299-308.
5. Alcaide P, Rodriguez-Pombo P, Ruiz-Sala P, *et al.* A new case of creatine transporter deficiency associated with mild clinical phenotype and a novel mutation in the SLC6A8 gene. *Dev Med Child Neurol* 2010; 52:215-7.
6. Comeaux MS, Wang J, Wang G, *et al.* Biochemical, molecular, and clinical diagnoses of patients with cerebral creatine deficiency syndromes. *Mol Genet Metab* 2013; 109:260-8.
7. Nota B, Ndika JDT, van de Kamp JM, *et al.* RNA sequencing of creatine transporter (SLC6A8) deficient fibroblasts reveals impairment of the extracellular matrix. *Human Mutation* 2014; 35:1128-35.
8. Edvardson S, Korman SH, Livne A, *et al.* L-Arginine: glycine amidinotransferase (AGAT) deficiency: clinical presentation and response to treatment in two patients with a novel mutation. *Mol Genet Metab* 2010; 101:228-32.
9. Verma A. Arginine: glycine amidinotransferase deficiency: a treatable metabolic encephalomyopathy. *Neurology* 2010; 75:186-8.
10. Dezortova M, Jiru F, Petrsek J, *et al.* 1H MR spectroscopy as a diagnostic tool for cerebral creatine deficiency. *Magma* 2008; 21:327-32.