

The use of AQP4-antibody testing in diagnosis Thai patients with neuromyelitis optica

^{1,2}Sasitorn Siritho MD, ³Metha Apiwattanakul MD, ¹Naraporn Prayoonwiwat MD

¹Division of Neurology, Department of Medicine, Siriraj Hospital, Mahidol University, Bangkok; ²Bumrungrad International Hospital, Bangkok, ³Department of Neurology, Prasat Neurological Institute, Bangkok, Thailand

Abstract

Background: There are several methods to detect AQP4-antibody which is essential for diagnosis neuromyelitis optica (NMO). **Objective:** To evaluate an accuracy of the commercially available kit compared with other available tests. **Methods:** One hundred and twelve patients who visited the multiple sclerosis (MS) clinic at Siriraj Hospital were tested for AQP4-antibody by cell-based assay with Sendai method (Postfix-CBA), a commercial kit (Prefix-CBA) and an indirect immunofluorescence tissue-based assay (IIF-TBA). The patients were classified to NMO, seropositive NMOSD (AQP4-pos NMOSD), seronegative NMOSD (AQP4-neg NMOSD), classic MS (CMS), atypical MS and clinical isolated syndrome (CIS). **Results:** Based on postfix-CBA, there were 26 NMO, 25 AQP4-pos NMOSD, 19 AQP4-neg NMOSD, 34 CMS, 4 atypical MS and 14 CIS. There were 5 (1 NMO, 2 AQP4-neg NMOSD, 2 CMS), 7 (1 NMO, 6 AQP4-pos NMOSD) and 2 patients (1 AQP4-neg NMOSD, 1 CIS) were seropositive only by CBA-kit, CBA-Sendai and IIF-TBA respectively. Sixteen patients were seropositive by both CBA but negative by IIF-TBA. Both CBA showed strong correlation.

Conclusions: CBA-kit is a relatively sensitive, comparable assay to detect anti-AQP4 antibody in Thai NMO patients. Since the kit may have a few false-negative and false-positive results, a more sensitive assay is necessary for a much more proper diagnosis in the future.

INTRODUCTION

Neuromyelitis optica (NMO) is an immune-mediated CNS disease typically affecting the optic nerve and spinal cord.¹⁻³ Since the discovery of serum NMO-IgG antibody in patients with NMO in 2004, a number of unexpected cases have been increasingly seen.⁴ In the original study, Lennon *et al.* detected NMO-IgG antibody from 45 North American patients with NMO and 12 Japanese patients with the opticospinal type of multiple sclerosis (OSMS).⁴ The sensitivity and specificity was reported to be 73% and 91% for NMO, and 58% and 100% for OSMS.⁴ In 2005, Lennon *et al.* found that NMO-IgG binds to aquaporin-4 (AQP4) water channel expressed on astrocyte foot processes lining the blood brain barrier in grey matter of spinal cord, periventricular and periaqueductal areas.⁵ Detection of serum AQP4-antibody is now one of the supportive criteria for NMO diagnosis.⁶ It not only serves as a disease marker but also plays a crucial role in the pathogenesis of NMO.^{7,8} Several methods available for AQP4-antibody detection include the original indirect immunofluorescence tissue-based assay

(IIF-TBA), enzyme-linked immunosorbent assay (ELISA), indirect immunofluorescence cell-based assay (IIF-CBA) with differences in sensitivity and specificity.¹⁰⁻¹⁷ Recent studies indicate that CBA is the most sensitive assay for detecting AQP4-antibody.¹⁴⁻¹⁶ Previous reports have shown high prevalence of NMO in Asia, especially Thailand, and they were problematic when diagnosing based on clinical manifestations only.¹⁸⁻²¹ However the sensitive CBA done by Tohoku University or Oxford University are difficult to conduct in Thailand and therefore, widely available testing kits with high sensitivity and specificity has replaced it. The primary objective of the study is to evaluate the accuracy of the commercially available kit to diagnose Thai patients with NMO/NMOSDs using a large Thai cohort which has a high prevalence of NMO/NMOSD.

METHODS

Patients and study design

This study was a retrospective observational study including Thai patients suspected of

idiopathic inflammatory demyelinating CNS diseases (IIDCD) who were visiting the multiple sclerosis (MS) clinic between May 1, 2009 and February 28, 2010, at Siriraj Hospital, Mahidol University, Thailand. The sera of the patients were first tested by cell-based assay with Sendai method (post-fixed CBA) and the results were published elsewhere.¹⁸ The same sera, which were stored at -80°C, were later tested using the other two methods participated in this study during November 2011 to May 2012. We made diagnosis by reviewing medical records with the knowledge of the results of AQP4 antibody serology by post-fixed CBA.

Diagnostic criteria with AQP4-antibody results by post-fixed CBA

We made diagnosis based on the following:

1. NMO was the patient who fulfilled NMO by Wingerchuk 2006 criteria.⁶
2. Seropositive NMOSD (AQP-pos NMOSD) was defined as patients who had positive AQP4-antibody but who not yet fulfilling Wingerchuk 2006 criteria.⁶
3. Seronegative NMOSD (AQP4-neg NMOSD) was defined as patients who fulfilled Wingerchuk 2007 criteria but who were negative for AQP4-antibody.¹⁹
4. Classic MS (CMS) was defined as patients who fulfilled McDonald 2010 Criteria.²⁰
5. Atypical MS was defined in patients who fulfilled McDonald 2010 Criteria but has some characteristics not commonly seen in CMS.
6. Clinically isolated syndrome (CIS) was defined in the patients with the first neurological event caused by inflammatory demyelination who did not meet McDonald 2010 Criteria.^{23,24}

AQP4 antibody testing

We already had the AQP4 antibody results by post-fixed CBA as stated in a previous study.¹⁸ Blinded to the previous results, two other methods including the tissue-based indirect immunofluorescence assay (IIF-TBA) and the cell based immunofluorescence method using commercial kit Euroimmun® (pre-fixed CBA) were tested.

Cell based assay by Sendai Method (Post-fixed CBA)

AQP4-live cells transfected human embryonic kidney cells (HEK293) with untagged AQP4-M23 isoform were incubated with diluted

serum, washed and incubated with fluorescein-conjugated goat anti-human IgG. Fixed cells were photographed with confocal microscopy, and antibody seropositivity was scored through comparison with mock-transfected cells that did not express AQP4. The serum was screened at a concentration 1:16. This assay was performed using methods described elsewhere.⁸

Cell based assay by commercial kit (Euroimmun®) (Pre-fixed CBA)

CBA was performed using Neurology Mosaics kit (EUROIMMUN, AG, Luebeck, Germany). CBA-kit uses HEK 293 cells transfected with recombinant full-length human AQP4, M1 isoform, to detect AQP4 antibodies and wild-type HEK 293 cells as a control substrate. According to the manufacturer's instruction¹⁰, 25 µL of 1:10 diluted sera was applied to slides on which mouse tissue or HEK cells were attached. After 30 minutes of incubation at room temperature, the slides were washed and fluorescein-labeled anti-human globulin was added. Fluorescence was observed with a microscope after 30 minutes of incubation. AQP4-antibody was considered positive when the cytoplasm of AQP4-transfected cells showed a flat, smooth, and fine granular fluorescence staining pattern.

Tissue-based indirect immunofluorescence assay (IIF-TBA)

The assay was done with the method described elsewhere⁵. It uses composite substrate of mouse tissue (cerebellum, midbrain and kidney). AQP4-antibody was detected with fluorescence-conjugated goat antibody to human IgG. The serum was screened at a concentration 1:120. The result is considered positive when the staining pattern of Virchow-Robin spaces, continuous pia, albuminal staining of microvessels in the cerebellar molecular layer, granular layer and white matter, pia and subpial of midbrain is present.

Statistical analysis

Subject characteristics were described using descriptive statistics, including means, standard deviation, median, minimum and maximum or frequencies and percentage. PASW Statistics (SPSS) version 18 software was used to perform the statistical analysis. We used a student t-test and Mann-Whitney U test for quantitative data and chi-square test or Fisher's exact test for qualitative

data. To compare the two diagnostic tests with post-fixed CBA for sensitivity, specificity, positive and negative predictive values and accuracy with 95% confident interval, we used only patients in category 1 and 2; NMO and AQP-pos NMOSD. Agreement between the AQP4 antibody results was assessed according to Kappa coefficients.²⁵ All *P*-values were two-tailed and ones <0.05 were considered to be statistically significant.

The study received approval from an ethical standards committee. All participants gave written informed consent.

RESULTS

From 135 patients suspected of IIDCD, 122 patients (92 female and 30 male) were tested by all 3 tests. Including the results on only post-fixed CBA, there were 26 NMO, 25 AQP4-pos NMOSD, 19 AQP4-neg NMOSD, 34 CMS, 4 atypical MS and 14 CIS.

Comparison of the clinical, MRI, and laboratory findings in AQP4 antibody-positive and AQP4 antibody-negative NMO/NMOSD patients (Table 1)

There were 48 AQP4-positive NMO/NMOSD patients and 22 AQP4-negative NMO/NMOSD patients. Of those 22 AQP4-negative NMO/NMOSD group, 3 were definite NMO. There were higher female prevalence (89.6 vs 50%), four times of number of the attacks (median of 4 vs 1, $p < 0.0001$), higher annualized relapse rate (median of 0.43 vs 0.30, $p = 0.015$), less presentation of bilateral optic neuritis as a first manifestation (6.3 vs 31.8%), more patients who fulfilled initial brain MRI McDonald 2010 criteria (23.3 vs 0%), and more CSF-pleocytosis (52.6 ± 214.4 vs 21.2 ± 73.2) in AQP4 antibody-positive group than in AQP4-negative group. There was no significant difference in age at onset, length of spinal cord lesion, presence of CSF-oligoclonal bands (CSF-OCB), number of spinal cord lesions and CSF-polymorphonuclear cells (PMN) between the two groups. There was a trend of more clinical brainstem manifestations and worsening of Expanded Disability Status Scale (EDSS) in AQP4-positive group; however, it was not significant.

Detection of AQP4-antibody among the three assays in different groups of the diseases based on the diagnosis by post-fixed CBA (Figure 1) and the correlation between each test (Table 2)

Totally, there were concomitant results in all

the three tests in 66 patients (54.1%) with seronegativity and 24 patients (19.7%) with seropositivity. Sixteen patients had AQP4-negative by IIF-TBA but who positive by the other two CBA. All of them were NMO and AQP4-pos NMOSD (Figure 1). There were 3 AQP4-positive NMOSD associated Sjogren's disease. According to the diagnosis using post-fixed CBA for detection AQP4-antibody, patients with NMO and AQP4-pos NMOSD had significantly higher seropositivity rate detected by pre-fixed CBA (88.5, 72%) than those determined by IIF-TBA (46.2, 52%), respectively. In our study, IIF-TBA had the least sensitivity among all assays, similar to the previous studies. Cell-based assays showed strong correlation (Kappa 0.758) between pre-fixed and post-fixed assays (Table 2).

There were 2 NMO and 16 NMOSD with AQP4-negative in all of the three assays (Table 3). For NMO with AQP4-antibody negative, both presented with ON and TM with normal brain MRI at onset and spinal cord involvement of >3 vertebral bodies.

There were 4 atypical MS patients. All had fulfilled McDonald criteria from the beginning and AQP4-antibody negative. One presented with recurrent unilateral ON, brainstem, spinal cord involvement of 2-3 VB and presence of CSF-OB but had CSF pleocytosis. One presented with recurrent unilateral ON and multifoci of 1-2 VB spinal cord involvement and CSF pleocytosis. Another one was a female with spinal cord lesion of 1-2 VB but with cord atrophy and the other one was multifoci of 1-2 VB spinal cord involvement, presence of CSF-OB but associated with ANCA seropositivity.

Only 2 patients (1 CIS and 1 AQP4-neg NMOSD) showed seropositivity in IIF-TBA but not with both CBA. The former was a 27-year-old man presented with brainstem involvement, presence of CSF-OB. One year after the study period he was diagnosed with MS after met the MRI criteria for dissemination in time and space then received IFN- β treatment and has had no new attack so far. The latter was a woman who presented with single event of spinal cord involvement of 4 VBs, absence for CSF-OBs and had normal brain MRI. She had positive anticardiolipin antibodies and later was diagnosed with antiphospholipid syndrome. The interpretation of this needed consideration. Based on the clinical manifestations, the former patient seemed to be CIS then typical MS later on. Therefore, the result in this case might be false positive. In contrast, the latter case could be NMOSD

Table 1: Clinical and laboratory features AQP4-negative and AQP4-positive NMO/NMOSD patients based on post-fix cell based assay

Parameter	AQP4- positive (n=48)	AQP4- negative (n=22)	P value
Sex; F:M (% female)	43:5 (89.6)	11:11 (50)	<0.0001
<i>Demographic data</i>			
Age at onset (years) (median, min-max)	35.5 (5.6,80.7)	37.0 (8.4,60.1)	0.942
Disease duration (years) (median, min-max)	7.6 (2.9,18.3)	4.2 (2.7,21.7)	0.013
Number of attack (times) (median, min-max)	4.00 (1,31)	1(1,7)	<0.0001
Annual relapse rate (times/year) (median, min-max)	0.43 (0.13,2.09)	0.30 (0.05,1.17)	0.015
EDSS (median, min-max)	3.75 (0,8.5)	3.25 (0,8.5)	0.051
MSSS ²⁸ (median, min-max)	7.54 (0.11,9.98)	6.57 (0.30,9.98)	0.349
<i>First clinical manifestation (%)</i>			
Optic neuritis	19 (39.6)	9 (40.9)	0.916
Bilateral ON	3 (6.3)	7 (31.8)	0.005
Cerebrum dysfunction	1(2.1)	0 (0)	0.495
Cerebellar dysfunction	1 (2.1)	0 (0)	0.495
Brainstem dysfunction	6 (12.5)	0 (0)	0.083
Myelitis	25 (52.1)	13 (59.1)	0.585
<i>Brain MRI</i>			
Initial MRI brain (% in those examined)	43 (89.6)	17 (77.3)	0.268
Initial MRI brain meeting McDonald 2010 Criteria (% in those examined)	10/43 (23.3)	0/17 (0)	0.005
<i>Spinal cord MRI</i>			
Initial cord MRI abnormal (% in those examined)	37/48 (77.1)	18/22 (81.8)	0.761
Number of lesions (mean ± SD)	1.22 ± 0.75	0.94 ± 0.42	0.248
Number of enhancing lesions (mean ± SD)	0.46 ± 0.56	0.33 ± 0.49	0.844
Length of the lesion (VBs) (median, min-max)	4.00 (0,15)	4 (0,19)	0.978
Length of lesion >3 VBs	25/37 (67.6)	13/18 (72.2)	0.726
Cord swelling	10/37 (27.0)	5/18 (27.8)	0.953
Cord atrophy	4/37 (10.8)	0/18 (0)	0.147
<i>Cerebrospinal fluid analysis (CSF)</i>			
CSF-WBC (cell/mm ³) (median, min-max)	7.0 (0,1380)	3 (0,340)	0.041
CSF-PMN (median, min-max)	0 (0,86)	0 (0,61)	0.117
CSF-OBs (% of those with positive test)	8/41(19.5)	4/21(19.0)	0.548
<i>Treatment with Azathioprine</i>	16/48 (33.3)	4/22 (18.2)	0.250

EDSS: expanded disability status scale; ON: optic neuritis; OBs: oligoclonal IgG bands
MSSS: Multiple sclerosis Severity Score; VB: vertebral bodies

Table 2A: Comparison the utility among the three tests for diagnosis of NMO *

Methods	Sensitivity (95% CI)	Specificity (95% CI)	PPV (95% CI)	NPV (95% CI)	Accuracy
IIF-TBA	52.1 (37.2-66.7)	100.0 (29.2-100)	100 (86.3 -100)	11.5(2.4 -30.2)	54.90
Pre-fix CBA	83.3 (69.8-92.5)	66.7(9.4-99.2)	97.6(87.1-99.9)	20.0(2.5-55.6)	82.35

*Use only patients who were diagnosed with NMO and AQP4-positive NMOSD

Table2B: Concordance Rates for the detection of AQP4-antibody in 122 sera between IIF-TBA, CBA-kit and CBA-Sendai

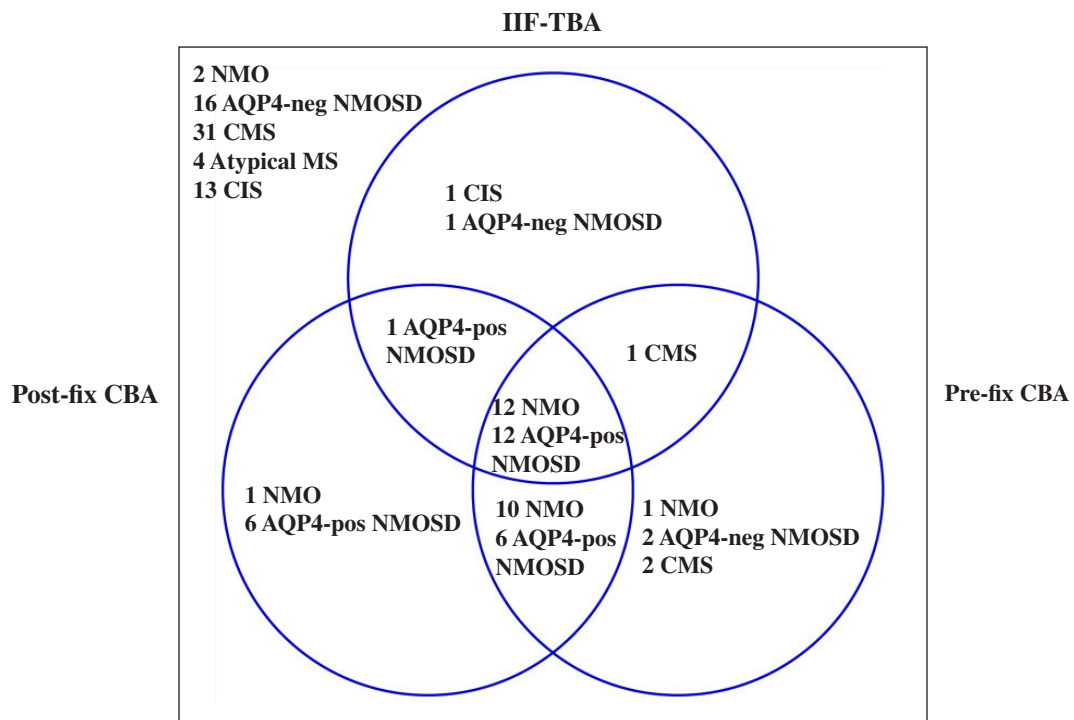
Methods	Co-negativity (%)	Co-positivity (%)	%agreement (Kappa value)
IIF-TBA vs Pre-fix CBA	75.3	49	0.546
IIF-TBA vs Post-fix CBA	73.2	49	0.518
Pre-fix CBA vs Post-fix CBA	82.9	74.1	0.758

95% CI: 95% confidence interval; PPV: positive predictive value; NPP: negative predictive value

IIF-TBA: indirect immunofluorescence AQP4 antibody testing with tissue assay

Pre-fix CBA: cell based indirect immunofluorescence AQP4 antibody testing with commercial kit by Euroimmun

Post-fix CBA: cell based indirect immunofluorescence AQP4 antibody testing with Sendai methods



IIF-TBA: indirect immunofluorescence AQP4 antibody testing with tissue assay, Pre-fix CBA: cell based indirect immunofluorescence AQP4 antibody testing with commercial kit by Euroimmun; Post-fix CBA: cell based indirect immunofluorescence AQP4 antibody testing with Sendai methods
 NMO: neuromyelitis optica, AQP4-pos NMOSDs: neuromyelitis optica spectrum disorders with positive AQP4-antibody, AQP4-neg NMOSDs: neuromyelitis optica spectrum disorders with negative AQP4-antibody, CMS: classic MS, Atypical MS: MS with some uncommon presentation, CIS: clinical isolated syndrome

Figure 1: Clinical diagnosis based on post-fix CBA and the results of AQP4 antibody with 3 different assays

Table 3: Patients who were diagnosed with NMO/NMOSD with AQP4-negative all three assays

Pt	Sex	Age at onset (yrs)	Clinical presentation	Brain MRI fulfilled McDonald 2010	Length of spinal cord lesions (VBs) (level)	CSF-OBs	CSF-WBC	EDSS	Disease duration (yrs)	ARR	Specific Rx
1*	F	26.1	Recurrent unilateral ON-TM	No	5(T8-12) with GdL	No	0	3.5	10.8	0.19	No Rx
2*	F	8.4	Recurrent bilateral ON-TM	No	3 (C4-6) with cord swelling	No	3	2	3.2	0.62	Aza
3	F	28.1	Single TM	No	3 (T2-5)c patchy enhance	Yes	25	6.5	7.8	0.13	No Rx
4	F	51.9	Single TM	No	4 (T8-11)c faint enhance	N/A	3	3.5	3.9	0.26	No Rx
5	F	29.5	Single Bilateral ON	Normal	0	No	3	2	13.8	0.07	No Rx
6	F	49.6	Single Bilateral ON	N/A	N/A	N/A	N/A	4	21.7	0.05	No Rx
7	F	50.2	Single Bilateral ON	Normal	N/A	No	9	3	3.7	0.27	No Rx
8**	F	18.6	Recurrent bilateral ON	No	N/A	No	18	4	3	1.00	No Rx
9**	F	48.9	Bilateral ON	Normal	0	No	1	4	2.7	0.37	No Rx
10	F	36.1	Recurrent TM	Normal	3 (C3-6,T9-10)	No	2	3.5	5.4	0.37	No Rx
11	M	25.6	Recurrent TM	N/A	4 (C3-6)	No	0	3	4.5	0.44	No Rx
12	F	60.1	Single TM	No	6(C5,T7-12)	N/A	3	8.5	3.7	0.27	No Rx
13	M	39.6	Recurrent TM	Normal	11 (T1-11)	No	13	3	5.1	1.17	No Rx
14	M	56.6	Single TM	Normal	6 (C2-7) with cord swelling	No	2	8	3.0	0.34	No Rx
15	F	50.7	Single TM	N/A	4(T10-L1, conus medullaris)	N/A	1	3.5	3.1	0.32	No Rx
16	M	35.0	Single TM	Normal	5(T5-12) with cord swelling	No	1	2	3.8	0.26	No Rx
17	M	16.7	Recurrent unilateral ON-TM-cerebellar	No	19 (whole cord)	Yes	15	0	8.5	0.70	IFN- β
18	M	42.8	Recurrent Brainstem-TM	Normal	3 (C2- to brainstem) with cord swelling	No	340	2	7.1	0.28	No Rx

CSF-OBs: cerebrospinal fluid oligoclonal bands; WBC: white blood cell; EDSS : expanded disability score scales; ARR: annualized relapse rate; Aza: azathioprine; N/A: not available; ON: optic neuritis; TM: transverse myelitis
Patient 1-2 was diagnosed with NMO

**receive methylprednisolone within 3 days before AQP4-antibody testing

Table 4: Clinical features of patients who had AQP4-antibody positive in post-fix but not pre-fix test

Pt	Sex	Age at onset (yrs)	Clinical presentation	Brain MRI fulfilled McDonald 2010	Length of spinal cord lesions (VBs) (level)	CSF-OBs	CSF-WBC	EDSS	Disease duration (yrs)	ARR	Specific Rx
1	F	35.5	Unilateral ON-recurrent TM and brainstem	Normal	3 (C4-6)	Yes	8	4	5.8	0.52	Aza
2	F	18.1	Recurrent brainstem dysfunction-single TM	yes	1-2 (C2-3)	Yes	3	0	7.1	0.42	AZA
3	F	30.8	Bilateral ON-/TM/brainstem	No	N/A	Yes	56	6	12.8	0.39	AZA
4	F	54.8	Unilateral ON	Normal	N/A	No	2	3	9.6	0.62	No Rx
5	F	38.3	Recurrent TM	Normal	5 (C2-6)	Yes	21	7	5.8	0.69	Mitox-antrone→Aza
6	F	69.9	Single brain-stem attack	Yes	1 (C1-2, T3,T10,T12, cervicomedullary junction)	No	44	3	2.9	0.35	Aza
7	F	44.5	Recurrent bilateral ON	No	0	N/A	0	8	14.7	0.88	Aza

Patient 1 was diagnosed with NMO; Patient 2-7 was diagnosed with NMOSD

CSF-OBs: cerebrospinal fluid oligoclonal bands; WBC: white blood cell; EDSS : expanded disability score scales; ARR: annualized relapse rate; Aza: azathioprine; N/A: not available; ON: optic neuritis; TM: transverse myelitis

associated with other autoimmune diseases or simply neuromanifestation in antiphospholipid syndrome. Therefore the interpretation was based on clinical manifestations of the patient at time. This case should be monitored longer until we can assure the diagnosis.

Seven patients (1 NMO, 6 AQP4-pos NMOSD) had positive results only with the CBA-Sendai (Table 4). For the 6 AQP4-pos NMOSD, all but one had spinal involvement ≥ 3 VBs. Without AQP4-antibody testing, two were initially diagnosed with MS. One presented with recurrent brainstem attacks and presence of CSF-OCB and brain MRI fulfilling McDonald criteria from the beginning; therefore she was diagnosed with MS and treated as such. Then she developed myelitis with few foci of short 1-2 VB involvement one year after the treatment with interferon-beta and positive AQP4-antibody at time of the attack. She then switched the treatment to azathioprine and so far has had no further attack (Patient 2). The other presented with optic- brainstem-spinal cord involvement with presence of CSF-OB, brain

MRI compatible with McDonald 2010 criteria. She was on IFN-b for 2 months, then developed brainstem attack with small patch lesion around the third ventricle and AQP4-antibody positive (Patient 3). These two cases presented earlier with presentation like MS; however continued monitoring and AQP4-antibody seropositivity helping in the diagnosis of NMO/NMOSD. The other 5 patients had clinical presentation of NMO and NMOSD but positive AQP4-antibody only with post-fixed CBA.

There were 5 patients who had AQP4-seropositivity only by pre-fixed CBA (Table 5). Unfortunately, none had spinal MRI at time of the attack. One who had pre-test diagnosis with NMO presented with recurrent bilateral ON, brainstem involvement and spinal cord of 4 VB involvement extending to cervicomedullary junction but had no available brain MRI at the beginning (Patient 1). For another two AQP4-neg NMOSDs, one had 2 episodes of bilateral ON with brain MRI not compatible with McDonald criteria and absence of CSF-OCB (Patient 2) and the other was a

Table 5: Clinical features of patients who AQP4-antibody positive in pre-fix but not post-fix test

Pt	Sex	Age at onset (yrs)	Clinical presentation	Brain MRI fulfilled McDonald 2010	Length of spinal cord lesions (VBs) (level)	CSF-OBs	CSF-WBC	EDSS	Disease duration (yrs)	ARR	Specific Rx
1	F	37.8	Recurrent bilateral ON/ TM/Brainstem (ANA 1:640)	N/A	4 (C2-5) with C-M junction	Yes	1	6	15.8	0.44	Aza
2	F	31.4	Recurrent bilateral ON with poor recovery	No	N/A	No	9	1	4.0	0.50	Aza
3	M	38.6	Single TM	Normal	5 (C2-6, T6-7)	Yes	13	2	7.4	0.13	Aza
4	M	45.1	Recurrent unilateral ON with good recovery	Yes	N/A	No	3	2	6.8	0.29	No Rx
5	M	21.7	Recurrent unilateral ON /single TM/2 brainstem	Yes	N/A	No	3	3.5	7.1	0.84	IFN-beta

Patient 1 was diagnosed with NMO, Patient 2-3 was diagnosed with NMOSD-neg

Patient 4-5 was diagnosed with typical MS

CSF-OBs: cerebrospinal fluid oligoclonal bands; WBC: white blood cell; EDSS : expanded disability score scales;

ARR: annualized relapse rate; Aza: azathioprine; N/A: not available; ON: optic neuritis; TM: transverse myelitis

female with monophasic spinal cord involvement with 5 VBs in length and presence of CSF-OCB (Patient 3). In a few patients like these two NMOSD patients, although negative by post-fixed CBA, using pre-fixed CBA would be necessary for proper diagnosis. For the other 2 CMS, one was presented with recurrent unilateral ON with good recovery (Patient 4). The other presented with optic-brainstem and spinal cord involvement and was treated with interferon-beta and has had no further attack (Patient 5). Both had absence of CSF-OCB and brain MRI findings compatible with McDonald 2010 criteria from the beginning. Perhaps these 2 patients may have presented false positive results by pre-fixed CBA; nevertheless they had some atypical findings for typical MS characteristics. For these patients, long term follow up would be prudent before final diagnosis.

There was 1 AQP4-pos NMOSD who had seropositivity with both IIF-TBA and post-fixed CBA but was negative with pre-fixed CBA. She had recurrent bilateral ON with history and findings of spinal cord involvement but no available spinal MRI at time of the attack and

an absence of CSF-OCB. She was treated with azathioprine and has had no further attack so far. For some reasons, this clinically definite NMOSD failed to be detected by pre-fixed CBA.

There was 1 CMS had seropositivity with IIF-TBA and pre-fixed CBA. She presented with unilateral optic neuritis, a few spinal cord lesions with 1-2 VB length and brain MRI compatible with McDonald 2010 criteria with the presence of CSF-OCB. For this typical MS patient, this case might have had false negative results.

DISCUSSION

The present study confirmed that Thai patients with IIDCD had high AQP4-antibody seroprevalence (39.3%).¹⁸ Similar to previous studies, our study showed that NMO/NMOSD patients with positive AQP4-antibody had more female prevalence, higher number of attacks and ARR and more CSF-pleocytosis than those with AQP4-negative. There was no significant different in age at onset, length of spinal cord lesion, presence of CSF-OCB, number of spinal cord lesions and CSF-PMN between the two groups.

The variation in the prevalence of NMO depends on selection of the patient and difference in diagnostic assays. Since NMO has a high disability index, we should not mistake the diagnosis which might lead to inappropriate treatment. Therefore we need a diagnostic test with high sensitivity and high positive predictive value. Recent study showed that CBA untagged AQP4-M23 with live cells is the best detection which increasing the sensitivity without specificity loss. It has more sensitive than the classic AQP4-M1 on fixed cells and much better than IIF-TBA.^{16,17} However using live cells in post-fixed CBA is more complicated, hard to reproduce and would be more costly than using pre-fixed CBA. In Thailand, we use pre-fixed CBA and IIF-TBA in general clinical practice. Our findings demonstrated that pre-fixed CBA had high comparable sensitivity with moderate specificity when compared to post-fixed CBA. The IIF-TBA had the lowest sensitivity among the three tests and showed only moderate agreement when compared with the other 2 CBA (Kappa =0.5) while the agreement between the 2 cell-based assays showed substantial concurrence (Kappa = 0.758). Otherwise, most of the results were consistent between the two methods. Therefore screening AQP4-antibody with pre-fixed CBA may be appropriate in helping

to sway the clinical opinion in cases of suspected NMO in Thailand.

However, there were discordant results between the tests (Table 6). The substrate used for AQP4-antibody detection by IIF-TBA was not human but mouse brain tissue which had somewhat different amino acid sequences. These might affect the sensitivity and specificity of the test. Although the IIF-TBA can detect both M1 and M23 isoform, all the assays using M23 can also detect all the antibodies against M1. Therefore, using the CBA not only lose the specificity but also improves the sensitivity.

Both pre-fixed and post-fixed CBA used recombinant human AQP4 as a substrate which may be closer to human tissue than those with IIF-TBA which use mouse tissue. There were some differences between the 2 cell based assays. Firstly, post-fixed CBA used untagged AQP4-M23 isoform live cells and with its conformation is able to form orthogonal arrays of particles (OAP) which are more easily detected by AQP4-antibody than the commercial pre-fixed CBA with AQP4-M1 isoform.¹⁶ Secondly, incubation of patient serum with pre-fixed CBA increased the nonspecific binding and generated higher noise to background ratio.¹⁷ Therefore this noise can possibly result in providing a false-positive result.

Table 6: Clinical diagnosis and the results of AQP4 antibody with 3 different assays

Clinical diagnosis without the result of AQP4-antibody (n)	Diagnosis with AQP4-antibody by post-fix CBA (n)	IIF-TBA	Pre-fix CBA	Post-fix CBA	N
NMO (2), OSMS (2), ONMOSDs(18), MS (33), CIS (11)	NMO (2), AQP4-neg NMOSD (16), CMS (31), atypical MS (4), CIS (13)	-	-	-	66
NMO (1), ONMOSDs(2), MS (2)	NMO (1), AQP4-neg NMOSD (2), CMS (2)	-	+	-	5
MS (1)	MS (1)	+	+	-	1
MS (1), other autoimmune diseases (1)	AQP4-neg NMOSD (1), CIS (1)	+	-	-	2
NMO (8), ONMOSDs(7), MS (7), CIS (1), other autoimmune	NMO (12), AQP4-pos NMOSD (12)	+	+	+	24
NMO (2), ONMOSDs (3), MS (2)	NMO (1), AQP4-pos NMOSD (6)	-	-	+	7
NMO (5), OSMS (2), ONMOSDs(4), MS (4), other autoimmune diseases (1)	NMO (10), AQP4-pos NMOSD (6)	-	+	+	16
MS (1)	AQP4-pos NMOSD (1)	+	-	+	1

IIF-TBA: indirect immunofluorescence AQP4 antibody testing with tissue assay, Pre-fix CBA: cell based indirect immunofluorescence AQP4 antibody testing with commercial kit by Euroimmun; Post-fix CBA: cell based indirect immunofluorescence AQP4 antibody testing with Sendai methods

NMO: neuromyelitis optica, AQP4-pos NMOSDs: neuromyelitis optica spectrum disorders with positive AQP4-antibody, AQP4-neg NMOSDs: neuromyelitis optica spectrum disorders with negative AQP4-antibody, ONMOSD: clinical suspected NMO with the recurrent or simultaneous ON or TM with equal or more than 3 VB spinal involvement, CMS: classic MS, Atypical MS: MS with some uncommon presentation, CIS: clinical isolated syndrome

The other possibility is post-fixed CBA detected M23 but pre-fixed CBA used M1 isoform which might cause difference in the results. Since AQP4 antibodies play a role in the pathogenesis of NMO and removal of AQP4 antibody by plasma exchange has been suggested as treatment for NMO.^{5,8,26} Detection of AQP4 antibody with a highly sensitive test would be beneficial for these patients.

There were 2 out of the 26 NMO patients (7.7%) and some patients with NMOSD who were AQP4-negative after testing by all of the three tests. Generally AQP4-negative NMO may be caused by the sensitivity of the test used or the antibody titer being lower than the detectable level after treatment with plasmapheresis or immunosuppressant. Therefore, testing for AQP4-antibody should be repeated if the index of suspicion for NMO/NMOSDs is high in particularly at the time of the attack. Moreover there might be other mechanisms or another antibody targeted at the dystroglycan macromolecular complex of the AQP4 molecule or other antigens such as myelin oligodendrocyte glycoprotein (MOG).²⁷ Some of these patients may have anti-MOG antibody positive.

Our study showed some differences in the results by the pre-fixed CBA compared with post-fixed CBA. We should consider the clinical information, incorporate the findings in MRI and the AQP4-antibody results altogether to make the diagnosis of NMO/NMOSD. In high suspicious cases, repeat AQP4-antibody testing and long term follow-up will disclose the exact diagnosis. We should be careful for the diagnosis of using pre-fixed CBA in cases like these. However, these findings demonstrated that pre-fixed CBA is one of the reliable tests for detection AQP4-antibody for diagnosis of NMO/NMOSD in Thailand.

Our study had a few limitations. Firstly, number of the patients was too small. Secondly, we did not have titer of AQP4-antibody to predict the clinical course or response to the treatments. A larger group of NMO/NMOSD tested with the best assay with live cells transfected, untagged AQP4-M23 isoform CBA using flow cytometric analysis is needed to study the characteristics of each group of the patients.

In conclusion, we confirmed that Thai NMO/NMOSD patients with AQP4-antibody positive had clinical characteristics similar to those seen in other countries. Our study showed that pre-fixed CBA is relatively more sensitive than IIF-TBA and is comparable in sensitivity to post-fixed CBA in detection AQP4-antibody in cases of suspected NMO/NMOSD in Thailand.

ACKNOWLEDGEMENTS

We are grateful to Professor Fujihara K, Dr. Nakashima I, Dr. Takahashi T for providing AQP4-antibody testing with cell based assay. And we are truly thankful Wanichada Kosolthammakorn M.T., Natakorn Sangnumpong B.Sc., Leatchai Wachiruttamungkur, M.Sc, Nopwan Siwasiriyantont, M.Sc. and Laddawan Champa M.Sc. for their technical support.

This study was supported by Siriraj Research Grant number IOR015532049.

REFERENCES

1. O'Riordan JI, Gallagher HL, Thompson AJ, *et al.* Clinical, CSF, and MRI findings in Devic's neuromyelitis optica. *J Neurol Neurosurg Psychiatr* 1996;60(4):382-7.
2. Wingerchuk DM, Hogancamp WF, O'Brien PC, Weinschenker BG. The clinical course of neuromyelitis optica (Devic's syndrome). *Neurology* 1999; 53(5):1107-14.
3. Cree BA, Goodin DS, Hauser SL. Neuromyelitis optica. *Semin Neurol* 2002; 22(2):105-22.
4. Lennon VA, Wingerchuk DM, Kryzer TJ, *et al.* A serum autoantibody marker of neuromyelitis optica: distinction from multiple sclerosis. *Lancet* 2004; 364(9451):2106-12.
5. Lennon VA, Kryzer TJ, Pittock SJ, Verkman AS, Hinson SR. IgG marker of optic-spinal multiple sclerosis binds to the aquaporin-4 water channel. *J Exp Med* 2005; 202(4):473-7.
6. Wingerchuk DM, Lennon VA, Pittock SJ, Lucchinetti CF, Weinschenker BG. Revised diagnostic criteria for neuromyelitis optica. *Neurology* 2006;66(10):1485-9.
7. Pittock SJ, Weinschenker BG, Lucchinetti CF, Wingerchuk DM, Corboy JR, Lennon VA. Neuromyelitis optica brain lesions localized at sites of high aquaporin 4 expression. *Arch Neurol* 2006; 63(7):964-8.
8. Takahashi T, Fujihara K, Nakashima I, *et al.* Anti-aquaporin-4 antibody is involved in the pathogenesis of NMO: a study on antibody titre. *Brain* 2007; 130(Pt 5):1235-43.
9. Long Y, Lu Z, Hu X. Serum-positive and -negative AQP4 antibody NMO in Chinese patients. *Can J Neurol Sci* 2012; 39(2):232-5.
10. Jarius S, Probst C, Borowski K, *et al.* Standardized method for the detection of antibodies to aquaporin-4 based on a highly sensitive immunofluorescence assay employing recombinant target antigen. *J Neurol Sci* 2010; 291(1-2):52-6.
11. Fazio R, Malosio ML, Lampasona V, *et al.* Anti-aquaporin 4 antibodies detection by different techniques in neuromyelitis optica patients. *Mult Scler* 2009;15(10):1153-63.
12. Hayakawa S, Mori M, Okuta A, *et al.* Neuromyelitis optica and anti-aquaporin-4 antibodies measured by an enzyme-linked immunosorbent assay. *J Neuroimmunol* 2008; 196(1-2):181-7.

13. Chan KH, Kwan JS, Ho PW, Ho JW, Chu AC, Ramsden DB. Aquaporin-4 autoantibodies in neuromyelitis optica spectrum disorders: comparison between tissue-based and cell-based indirect immunofluorescence assays. *J Neuroinflammation* 2010; 7:50.
14. Waters PJ, McKeon A, Leite MI, *et al.* Serologic diagnosis of NMO:A multicenter comparison of aquaporin-4-IgG assays. *Neurology* 2012; 78:665-71.
15. Sato DK, Nakashima I, Takahashi T, *et al.* Aquaporin-4 antibody-positive cases beyond current NMO spectrum disorders diagnostic criteria. *Neurology* 2013; 80(24):2210-6.
16. Marignier R, Valnet RB, Giraudon P, *et al.* Aquaporin-4 antibody-negative neuromyelitis optica: Distinct assay sensitivity-dependent entity. *Neurology* 2013; 80(24):2194-200.
17. Fujihara K, Leite M. Seronegative NMO:A sensitive AQP4 antibody test clarifies clinical features and next challenges. *Neurology* 2013; 80(24):2176-7.
18. Siritho S, Nakashima I, Takahashi T, Fujihara K, Prayoonwiwat N. AQP4 antibody-positive Thai cases: clinical features and diagnostic problems. *Neurology* 2011; 77(9):827-34.
19. Kira J. Multiple sclerosis in the Japanese population. *Lancet Neurol* 2003; 2(2):117-27.
20. Osoegawa M, Kira J, Fukazawa T, *et al.* Temporal changes and geographical differences in multiple sclerosis phenotypes in Japanese: nationwide survey results over 30 years. *Mult Scler* 2009; 15(2):159-73.
21. Chong HT, Tan CT. A review of multiple sclerosis with Asian perspective. *Med J Malaysia* 2008; 63(5):356-61.
22. Wingerchuk DM, Lennon VA, Lucchinetti CF, Pittock SJ, Weinshenker BG. The spectrum of neuromyelitis optica. *Lancet Neurol* 2007; 6(9):805-15.
23. Polman CH, Reingold SC, Banwell B, *et al.* Diagnostic criteria for multiple sclerosis: 2010 revisions to the McDonald criteria. *Ann Neurol* 2011; 69(2):292-302.
24. Tintore M, Rovira A, Martinez MJ, *et al.* Isolated demyelinating syndromes: comparison of different MR imaging criteria to predict conversion to clinically definite multiple sclerosis. *AJNR Am J Neuroradiol* 2000; 21(4):702-6.
25. Cohen J. A coefficient of agreement for nominal scales. *Educational and Psychological Measurement* 1960; 20:37-46.
26. Watanabe S, Nakashima I, Misu T, *et al.* Therapeutic efficacy of plasma exchange in NMO-IgG-positive patients with neuromyelitis optica. *Mult Scler* 2007; 13(1):128-32.
27. Kitley J, Woodhall M, Waters P, *et al.* Myelin-oligodendrocyte glycoprotein antibodies in adults with a neuromyelitis optica phenotype. *Neurology* 2012; 79(12):1273-7.