

Moyamoya syndrome associated with vitamin B12 deficiency and hyperhomocysteinemia in a child

Rajesh Verma, Prakash Kori, HN Praharaj, Mani Gupta

Department of Neurology, Chhatrapati Shahuji Maharaj Medical University, Lucknow UP, India

Abstract

Moyamoya disease is a rare clinical disorder, characterized by chronic, progressive occlusion of supraclinoid internal carotid artery and proximal portions of the anterior and middle cerebral arteries, and consequent development of collateral vessels seen on imaging as puff of smoke appearance. Although the pathophysiology is unclear, various hematologic disorders have been associated with development of the moyamoya syndrome. We report a case of moyamoya syndrome in a 3 yr old girl who presented with recurrent ischemic strokes. The angiography was suggestive of moyamoya syndrome. The serum vitamin B12 level was remarkably low with bone marrow picture of megaloblastic anemia. There was also hyperhomocysteinemia. Moyamoya syndrome has not been previously reported to be associated with vitamin B12 deficiency. We propose that vitamin B12 deficiency with hyperhomocysteinemia could result in greater risk for arterial thrombosis and thus caused the moyamoya syndrome in our patient.

INTRODUCTION

Moyamoya syndrome is a rare, idiopathic progressive arteriopathy, which is an uncommon cause of both ischemic and hemorrhagic stroke. It is characterized by progressive stenosis and occlusion of the intracranial circulation with extensive collaterals, producing angiographic *puff of smoke* appearance.¹ Young females are more commonly affected. Multiple factors are responsible for Moyamoya disease with familial predisposition in 7 % of patients. The susceptibility loci have been found on chromosomes 3p, 6p, 17q, and band 8q23.²

Moyamoya syndrome has been reported with varied hematological disorders including Fanconi's anemia, sickle cell disease and thalassemias.^{3,4} This is the report of a 3 year old girl, who presented with ischemic stroke from Moyamoya syndrome. The patient was also found to have severe vitamin B12 deficiency, with megaloblastic anaemia and hyperhomocysteinemia. The association of Moyamoya syndrome and vitamin B12 deficiency has not been previously reported.

CASE REPORT

A 3 year old female presented with recurrent strokes with two episodes of acute hemiparesis. She developed Broca's aphasia a week ago. There was no past history of epileptic seizures. The

patient's birth history was uneventful with normal development of milestones. She was exclusively breast fed till 4 months of age, and was weaned off breast milk after that. The vaccination history was normal. The patient has two female siblings who were healthy, and there was no history of similar illness in the family. The patient was a strict vegetarian. She consumed milk, and less often also milk products. On examination, vital signs were normal. General examination showed pallor with no other abnormal findings. Central nervous system examination revealed Broca's aphasia with hypertonia and reduced power (Grade 3 according to MRC grading) in all four limbs. The deep tendon reflexes were exaggerated in all limbs with bilateral plantar extensor response. The rest of neurological examination was within normal limits.

Routine haemogram showed low haemoglobin (8 g %) with normal total leukocyte and platelet count. The other serum biomarkers including serum creatinine, random blood sugar, electrolytes and liver function test were within normal limits. Erythrocyte sedimentation rate was not raised (10 mm/hour). The chest X-ray did not reveal any abnormality, and Mantoux test was negative. Abdominal ultrasound was normal and did not demonstrate thickened loops or enlarged lymph nodes to suggest tuberculosis. Serum vitamin B12 level was significantly low at 87.32 pg/dl

(normal 243pg/dl-894pg/dl). Serum folate level was normal with raised serum homocysteine at 18 $\mu\text{mol/L}$ (normal 4-8 $\mu\text{mol/L}$). Iron studies including serum iron, total iron binding capacity and ferritin levels were within normal limits. Peripheral blood smear showed macrocytic anemia. The patient underwent bone marrow study which demonstrated hypercellular marrow with megaloblastic red cell precursors (Figure 1). Stool examination for parasites including microscopic examination for ova and cysts were negative. The urinary estimation of orotic acid was not suggestive of orotic aciduria.

Magnetic resonance imaging (MRI) of cranium showed bilateral anterior cerebral artery and left middle cerebral artery territory infarction (Figure 2). Magnetic resonance angiography (MRA) showed poor visualization of both middle cerebral artery (MCA) and distal part of right anterior cerebral artery (ACA) with multiple collaterals noted in region of circle of Willis and in bilateral MCA territory region with puff of the smoke appearance (Figure 3).

The patient was subjected to evaluation of

hypercoagulable state. The tests were all normal. This included activated protein C resistance, anticardiolipin antibody, antithrombin III, D dimer, Factor V Leiden, fibrinogen, lupus anticoagulant, anticardiolipin antibodies, partial thromboplastin time, protein S and protein C. Echocardiography was also normal. The serology for human immunodeficiency virus, herpes zoster, dengue, Japanese encephalitis, leptospirosis, were negative. Other investigations which were normal included: Cerebrospinal fluid examination, thyroid function test (T3, T4, thyroid stimulating hormone) and thyroid antibodies; tests for tuberculosis; serum electrophoresis, angiotensin converting enzyme, rheumatoid factor, and antinuclear cytoplasmic antibody.

The patient was diagnosed to have moyamoya syndrome associated with vitamin B12 deficiency. She was treated with regular vitamin B12 injections and aspirin. She recovered partially at 3 months with improved muscle power (Grade 3+ in left upper and lower limbs and Grade 4 in right upper and lower limb) and speech fluency.

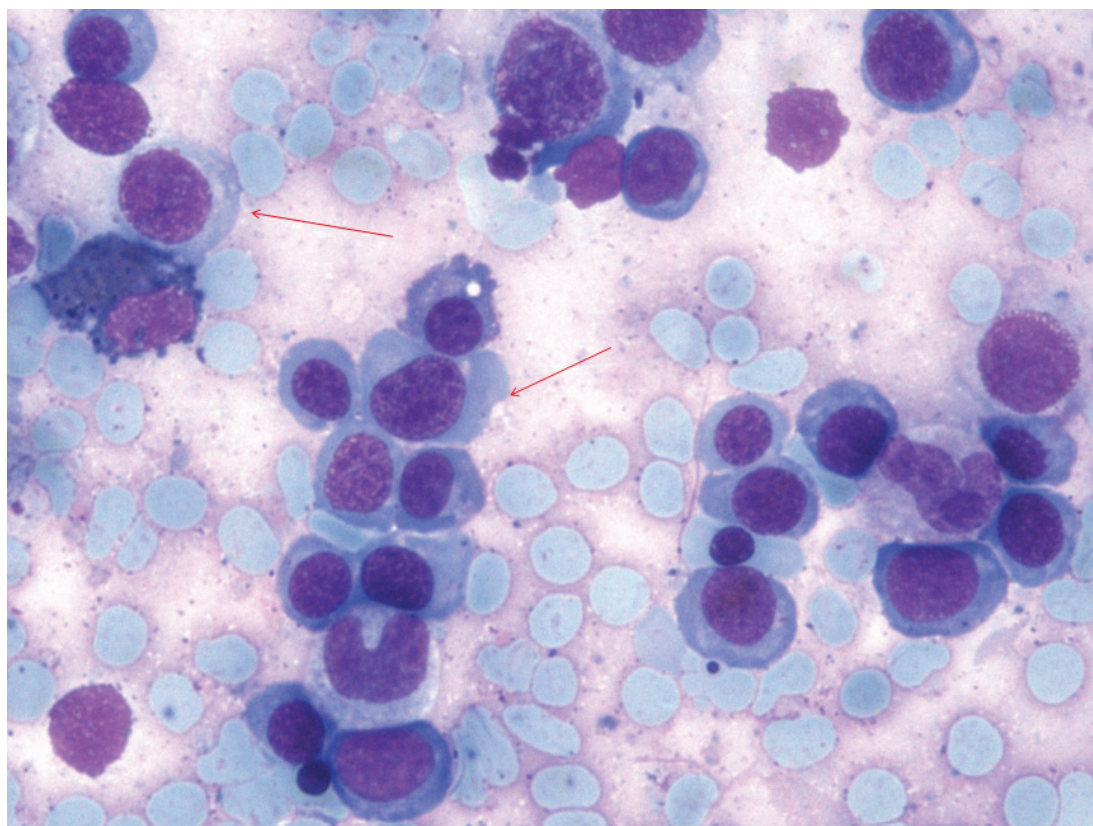


Figure 1. Bone marrow aspirate smear on 100 x magnification under oil immersion with leishman stain, depicting hypercellular marrow with megaloblasts (arrows).

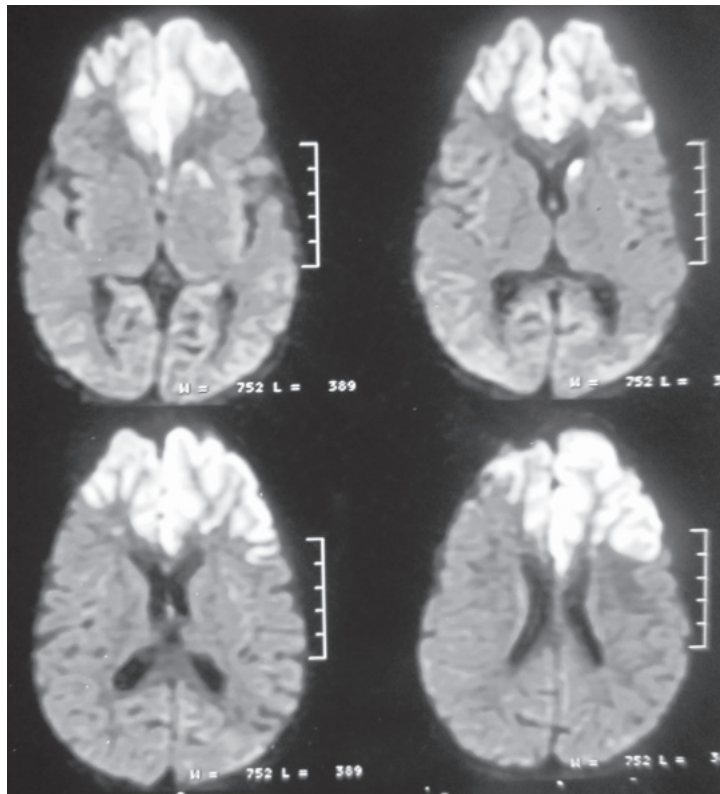


Figure 2. Diffusion weighted MRI demonstrated restricted diffusion in bilateral anterior cerebral and left middle cerebral artery territory suggestive of infarction.

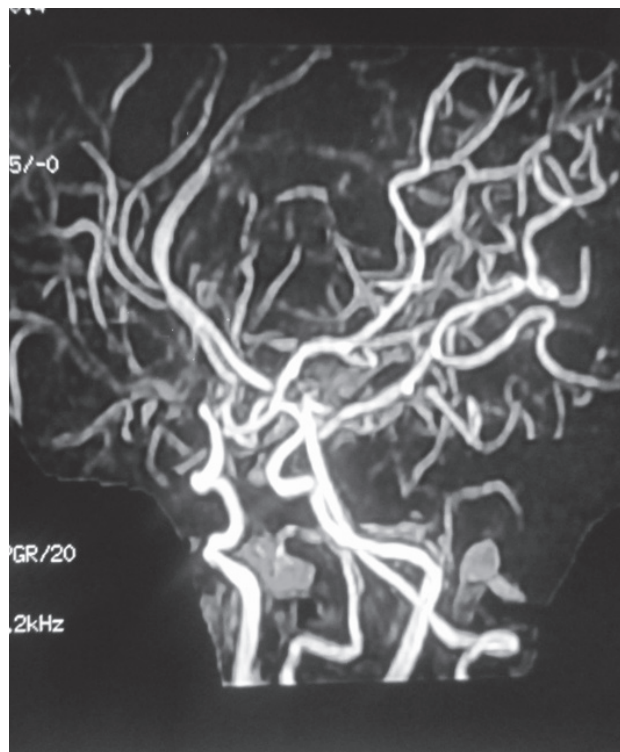


Figure 3. MRA revealed tuft of collaterals (puff of the smoke appearance) indicative of moyamoya syndrome.

DISCUSSION

Moyamoya syndrome is a rare disease, characterized by stenosis of vasculature at circle of Willis, caused by intimal fibrocellular thickening. The female to male ratio is 1.8:1, age ranging from 6 months to 67 years with the highest peak in the first decade.⁵ The common manifestation in young patients is ischemic stroke, while adults mainly manifested with intracranial hemorrhage. Cerebral angiography is mainstay for diagnosis of Moyamoya syndrome. Our patient presented with multiple infarcts. Her MRA revealed stenosis of bilateral anterior and left middle cerebral artery along with collaterals at base of brain. She was diagnosed to have moyamoya syndrome associated with vitamin B12 deficiency and hyperhomocysteinemia.

Moyamoya syndrome has been known to occur with hypercoagulable states and hyperviscosity syndromes.^{6,7} The laboratory workup ruled out these conditions in our patient. The mechanism for the development of the moyamoya vessels also include ischemia, vessel intima and medial wall proliferation, endothelial edema and occlusion in sickle cell anemia.⁸ In Moyamoya syndrome due to thrombocytopenia, hyperviscosity, platelet dysfunction, impairment in arachidonic acid metabolism and neutrophil mediated platelet aggregation have been implicated.⁶

Our patient with moyamoya syndrome has hyperhomocysteinemia. A case was reported of quasi moyamoya syndrome, who manifested with left sided hemiparesis. The patient was heterozygote for homocystinuria. The authors suggested for evaluation of homocysteine metabolism in paediatric stroke patients.⁹ In various studies, hyperhomocysteinemia was thought to injure vascular endothelium. The various mechanisms proposed for homocysteine related cerebrovascular disease are endothelial dysfunction, smooth muscle cell hyperplasia and increased oxidized lipids.¹⁰ We hypothesized that in our patient vitamin B12 deficiency and associated increased homocysteine levels could led to stenosis and occlusion of terminal part of bilateral internal carotid vessels resulting in moyamoya syndrome.¹¹

Pharmacologic therapy for Moyamoya disease is disappointing. Therapy is directed at prevention of further strokes.¹² Our patient was treated with antiplatelet agent aspirin and vitamin B12 supplementation. The patient's condition gradually improved over the ensuing months with partial resolution of her quadriplegia.

The patient is currently on aspirin and vitamin B12 supplementation and awaiting cerebral revascularisation surgery.

In conclusion, we report here the first case of moyamoya syndrome associated with vitamin B12 deficiency and hyperhomocysteinemia. We propose that vitamin B12 deficiency with hyperhomocysteinemia could result in greater risk for arterial thrombosis and thus caused the moyamoya syndrome in our patient. We believe the role of vitamin B12 deficiency in moyamoya syndrome should be further explored.

REFERENCES

1. Suzuki J, Takaku A. Cerebrovascular "moyamoya" disease; A Disease showing abnormal net-like vessels in base of brain. *Arch Neurol*. 1969; 20:288-99.
2. Weinberg DG, Arnaout OM, Rahme RJ, Aoun SG, Batjer HH, Bendok BR. Moyamoya disease: a review of histopathology, biochemistry, and genetics. *Neurosurg Focus* 2011; 30:E20.
3. Dobson SR, Holden KR, Nietert PJ, et al. Moyamoya syndrome in childhood sickle cell disease: a predictive factor for recurrent cerebrovascular events. *Blood* 2002; 99:3144-50.
4. Fukuyama Y, Osawa M, Kanai N. Moyamoya disease (syndrome) and the Down syndrome. *Brain Dev* 1992; 14:254-6.
5. Baba T, Houkin K, Kuroda S. Novel epidemiological features of moyamoya disease. *J Neurol Neurosurg Psychiatry* 2008; 79(8):900-4.
6. Lazzaro MA, Cochran EJ, Lopes DK, Prabhakaran S. Moyamoya syndrome in an adult with essential thrombocytopenia. *Neurol Int* 2011; 3(1):e3.
7. Kornblihtt LI, Cocorullo S, Miranda C, et al. Moyamoya syndrome in an adolescent with essential thrombocytopenia: successful intracranial carotid stent placement. *Stroke* 2005; 36:E71-3.
8. Vernet O, Montes JL, O'Gorman AM, Baruchel S, Farmer JP. Encephaloduroarterio-synangiosis in a child with sickle cell anemia dan moyamoya disease. *Pediatr Neurol* 1996 ;14:226-30.
9. van Diemen-Steenvoorde R, van Nieuwenhuizen O, de Klerk JB, Duran M. Quasi-Moyamoya disease and heterozygosity for homocystinuria in a five-year-old girl. *Neuropediatrics* 1990; 21:110-2
10. McCully KS. Homocysteine and vascular disease. *Nat Med* 1996; 2:386-9.
11. Hasan A, Hunt BJ, O'Sullivan M, et al. Homocysteine is a risk factor for cerebral small vessel disease, acting via endothelial dysfunction. *Brain* 2004; 127:212-9.
12. Scott RM, Smith ER. Moyamoya disease and moyamoyasyndrome. *NEnglJMed*2009;360:1226-37.