

Development of marked striatal hand with antiparkinsonian medication withdrawal during traditional (Ayurvedic) medicine treatment for Parkinson's disease

Shen-Yang Lim MD FRACP, Khean Jin Goh MBBS FRCP, Amir Azlan Zain MBBS MRCP, Norlisah Ramli MBBS FRCP, *Yeun-Mun Choo BSc PhD, *Guan Huat Tan BSc PhD

Faculty of Medicine (Divisions of Neurology, Rheumatology, and Neuroradiology), University of Malaya, *Chemistry Department, Faculty of Science, University of Malaya, Kuala Lumpur, Malaysia

Abstract

Ayurveda is a traditional medical system used widely in India and increasingly worldwide. Here, we report on a patient with Parkinson's disease (PD) who developed marked striatal hand with antiparkinsonian medication withdrawal during Ayurvedic medicine treatment for her PD. Although a direct role for the Ayurvedic medicines in inducing the hand deformity cannot be excluded, we propose that severe dopaminergic deficiency (due to prolonged withdrawal of antiparkinsonian medications in the context of long-standing PD) was probably the main culprit in our patient.

INTRODUCTION

Ayurveda is a traditional medical system used widely in India and increasingly worldwide, but there are growing safety concerns.^{1,2} Here, we report on a patient with Parkinson's disease (PD) who developed marked striatal hand with antiparkinsonian medication withdrawal during Ayurvedic medicine treatment for her PD. We believe that our report has important implications given the widespread and increasing use of this system of treatment.

CASE REPORT

Our patient is a 58-year-old woman of Indian ethnicity, diagnosed with PD in 2001 (onset with right-sided symptoms). Although she responded well to levodopa, motor response complications including severe leg dyskinesia developed. She had no history of rheumatological symptoms. In October 2008, she travelled to an Ayurvedic treatment centre in Cochin, India to undergo six months of treatment for her PD. Her medications at that time consisted of levodopa/carbidopa/entacapone 150/37.5/200 mg and slow-release levodopa/benserazide 100/25 mg (both tid), trihexyphenidyl 1 mg tid, and selegiline 5 mg/d. She had never received ergot dopamine agonists. Multiple preparations were administered orally (these were labelled

simply as "Arishtam", "Avarthanam", "Bhoona", "Cheriya Rasnadi Kashayam", "Chooranam", "Dasamoolakatuthrayam", "Ghee", "Kashayam", "Legyam", "Rasa Thailam", "Sivagulika", and "Mixed Thailam" - our attempts to contact the Ayurvedic practitioner for further details about the treatment regimen were unsuccessful), as well as a skin paste and nasal drop. As part of the treatment regime, her PD medications were tapered over the first month, then stopped completely for the remaining five months. Less than 3 months into her treatment course, she developed bilateral hand pain and deformity. The pain improved, but the deformity progressively worsened over the next few months. Her parkinsonism also worsened and she required assistance for all personal care.

In April 2009, her PD medications were resumed (levodopa-equivalent daily dose approximately 1.5x that of her baseline dose), with improvement of parkinsonism to baseline, but no improvement in the hand deformity (Figure 1). Investigations were normal or negative, including hand X-Ray and ultrasound, erythrocyte sedimentation rate, rheumatoid factor, antinuclear antibody, nerve conduction study and electromyography, and brain and cervical spine MRI. There were no atrophic or signal changes in the brain, either on T1, T2 or gradient-echo sequences, to suggest metal toxicity or an atypical parkinsonian syndrome. Central motor conduction

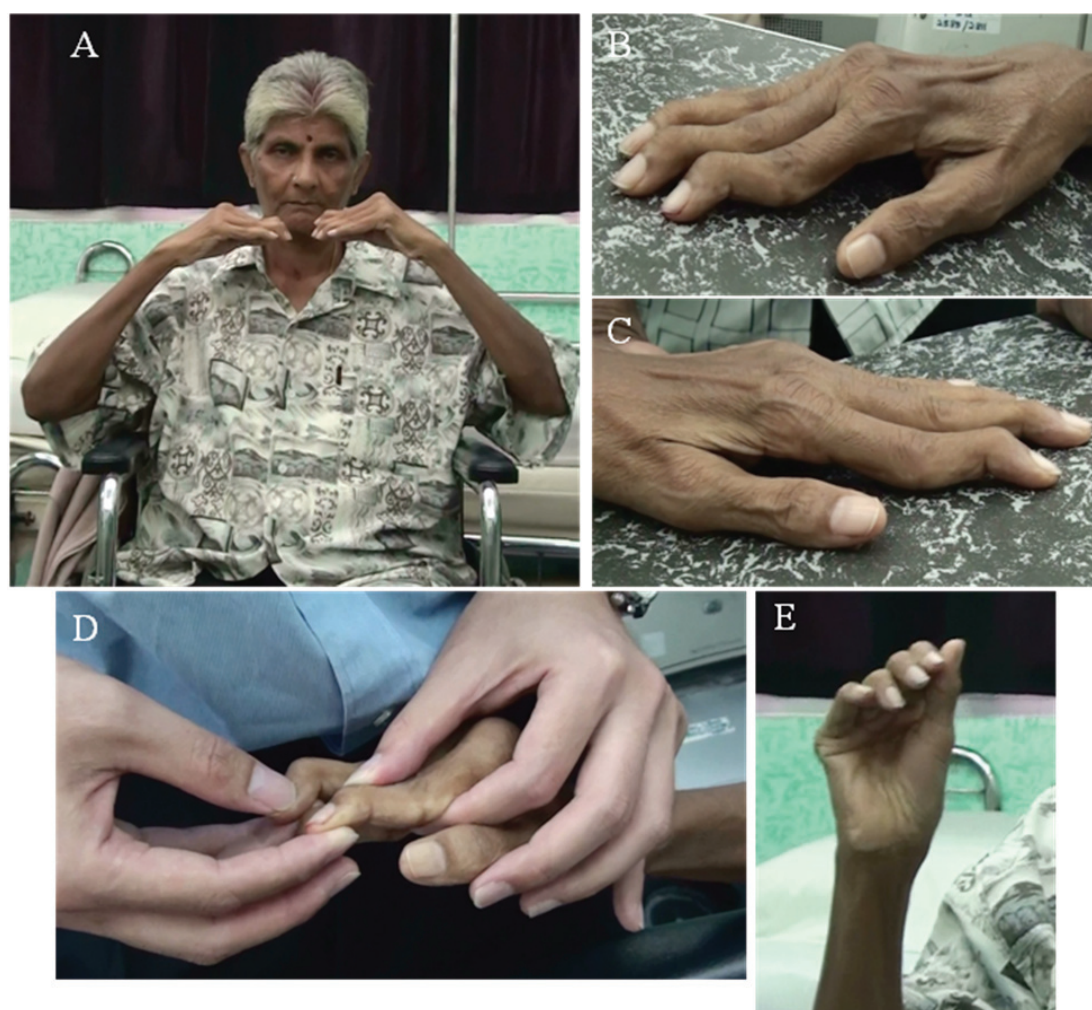


Figure 1. Striatal hands (A), with pronounced flexion of the metacarpophalangeal joints, hyperextension of the proximal interphalangeal joints, and flexion of the distal interphalangeal joints, right (B) worse than left (C). Many of the right hand joints could not be passively straightened (D). Patient attempting (but unable) to make a fist (E). There was no evidence of joint inflammation, rheumatoid nodules, or psoriatic plaques. Written informed consent for publication of these images has been obtained from the patient.

times, investigated using transcranial magnetic stimulation, were normal. Samples of the patient's leftover Ayurvedic medicines were available for trace metal analysis; the lead, mercury and arsenic content was found to be comparable with levels previously reported for commonly available Ayurvedic products.¹ Unfortunately, blood and urine samples sent to check for metals levels were lost. Botulinum toxin injections into the lumbrical and flexor digitorum profundus muscles resulted in modest improvement only.

DISCUSSION

Striatal hand and foot deformities are not uncommon in PD.³ To our knowledge, however,

there have been no reports of this complication developing during PD medication discontinuation in conjunction with traditional medicine treatment. This case draws attention to the potential dangers of such a course of treatment. In addition to disfigurement and pain, these deformities may cause substantial functional disability. The pathogenesis of striatal deformities remains poorly understood, but may involve decreased striatal dopamine, dystonia, parkinsonian rigidity, and/or fibrosis.³ A direct correlation with striatal dopaminergic deficiency has been postulated and appears to be, in our opinion, the main culprit in our patient. Nevertheless, cases are typically not correctable with dopatherapy⁴, perhaps due to the development of irreversible contractures. In

line with the dopaminergic deficiency hypothesis, the side of worse striatal deformity in our patient was also the more parkinsonian side, as previously reported³, and cases (like ours) tend to involve patients with longer PD duration⁴ and severe dyskinesia.⁴

Toxic metals, especially lead, mercury, and arsenic, are present in many Ayurvedic preparations.^{1,2} Therefore, the possibility that metal toxicity (or toxicity from other ingredients) may have played a role here should also be considered. Nevertheless, the neuroimaging changes that have been reported in such cases⁵ were not observed in our patient, and markedly elevated levels of metals were not found in the samples tested. We were unable to find any reports on development of dystonia or parkinsonism due to the use of Ayurvedic medicines, although this may well relate to under-reporting of adverse reactions.² We also cannot exclude the possibility that the patient's striatal deformity would have occurred as part of the natural history of her PD, but the close temporal relationship between the Ayurvedic treatment course and development of this complication over several months (instead of over 1-2 years, as previously reported for most cases)⁴ argues against this. The patient had been attending three-monthly follow-up at our neurology clinic for several years without any sign at all of this complication developing.

REFERENCES

1. Saper RB, Phillips RS, Sehgal A, *et al.* Lead, mercury, and arsenic in US- and Indian-manufactured Ayurvedic medicines sold via the Internet. *JAMA* 2008; 300:915-23.
2. Thatte U, Bhalerao S. Pharmacovigilance of Ayurvedic medicines in India. *Ind J Pharmacol* 2008; 40(Suppl 1):S10-S12.
3. Ashour R, Tintner R, Jankovic J. Striatal deformities of the hand and foot in Parkinson's disease. *Lancet Neurol* 2005; 4:423-31.
4. Hu MT, Bland J, Clough C, Ellis CM, Chaudhuri KR. Limb contractures in levodopa-responsive parkinsonism: A clinical and investigational study of seven new cases. *J Neurol* 1999; 246:671-6.
5. Rutchik JS. Occupational and environmental encephalopathies: Heavy metals. *MedLink Neurology* (www.medlink.com) (accessed 10 Feb 2010).