

Spinal cord meningioma in a case of myotonic dystrophy

Dheeraj Khurana, Human Sinha, *Rajesh Chhabra, Sudesh Prabhakar

Department of Neurology and *Neurosurgery, Postgraduate Institute of Medical Education and Research, Chandigarh, India

Abstract

The myotonic dystrophies (DMs) are autosomal dominant disorders, subdivided by their genetic defect into DM1 and DM2 and characterized by gradually progressive muscle weakness, myotonia, cataracts, endocrine disturbances and functional abnormalities of the cardiorespiratory and gastrointestinal tract. We report the unusual coexistence of spinal cord meningioma in a patient of myotonic dystrophy. As per our knowledge, this is the second case of a meningioma reported with myotonic dystrophy in the literature.

INTRODUCTION

The myotonic dystrophies (DMs), subdivided by their genetic defect into DM1 and DM2, are autosomal dominant multisystemic disorders characterized by gradually progressive muscle weakness, typical physiognomy, myotonia, cataracts, endocrine disturbances and functional abnormalities of the cardiorespiratory and gastrointestinal tract.¹ Two mutations can cause the disease: MD1, which is a CTG triplet repeat expansion of the DMPK gene on chromosome 19q, and MD2, which is a CCTG expansion in the ZNF9 gene on chromosome 3q.² Cerebral atrophy and white matter lesions are the usual findings on imaging.³ We report the occurrence of spinal cord meningioma in a patient with myotonic dystrophy.

CASE REPORT

A 37-year-old woman was referred to our outpatient service with the diagnosis of bilateral foot drop and a thoracic spinal cord meningioma. On evaluation, there was a history of weakness of both upper and lower limbs having onset in proximal muscles since 5 years earlier. Her weakness started in the upper limbs proximally followed by proximal muscle weakness of lower limbs a month later. After 3 years of onset of weakness, she developed weakness in the distal muscles of lower limbs as well. Her weakness was gradually progressive since then. There was no history of numbness or sensory loss, bladder

or bowel symptoms. There was no neck or truncal weakness. Examination revealed a characteristic 'hatchet face' and 'swan neck' and clinical myotonia on hand grip with percussion myotonia over thenar eminence and wrist extensors. There was no cataract. One of her sisters had similar facial appearance without any muscular weakness, but she refused medical examination. The electrocardiogram of the patient showed a left bundle branch block. The transthoracic echocardiogram however, was unremarkable. Fasting blood sugar and glucose tolerance test were normal. Needle electromyography revealed widespread myotonia with waxing and waning amplitude and frequency of the motor unit action potentials (MUAPs). MUAPs had normal morphology and recruitment pattern. Genomic DNA amplification revealed CTG triplet elongation in the DMPK gene consistent with myotonic dystrophy type 1. The MRI of cervicodorsal spine which was done prior to her referral to our center showed an intradural mass lesion at the level of D1-D2 with features suggestive of meningioma (Figure 1). It was surgically resected and histology was consistent with the morphology of a meningotheelial meningioma. To rule out similar lesions in the brain, a contrast enhanced cranial CT scan (Figure 2) was done which was unremarkable.

DISCUSSION

Myotonic dystrophy is uncommon in the Indian population with a prevalence of about

Address correspondence to: Dr Dheeraj Khurana, Associate Professor, Department of Neurology PGIMER, Chandigarh 160012, India.
E-mail: dherajk@yahoo.com

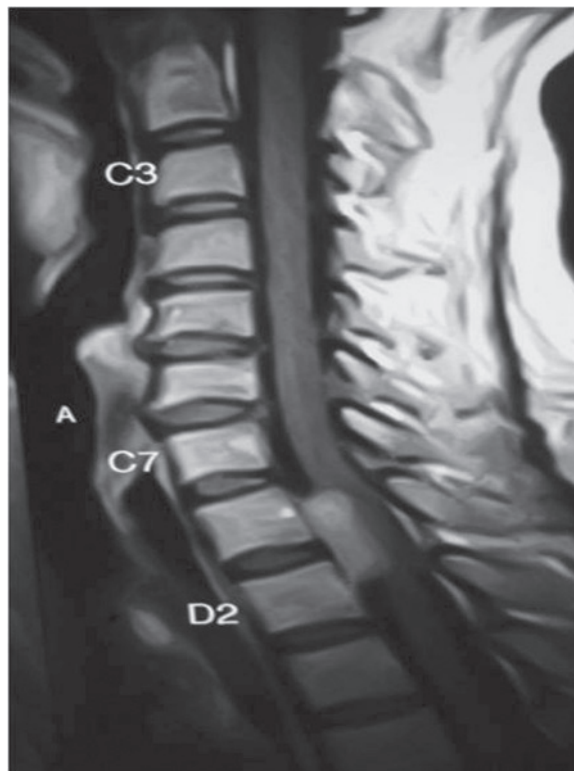


Figure 1. MRI dorsal spine (T1W sagittal image) showing an intradural mass lesion at the level of D1 and D2 with 'positive dural tail sign'

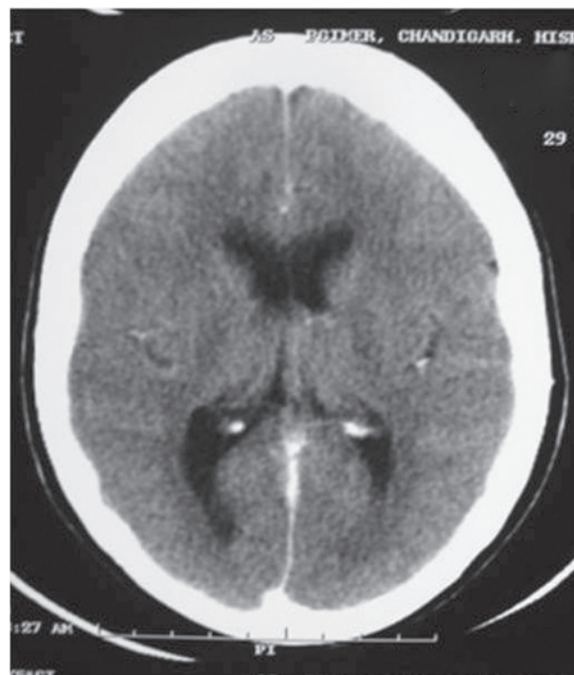


Figure 2. Contrast enhanced computed tomography of brain showing a normal study.

~8% of all muscular dystrophies.⁴ Myotonic dystrophy involves multiple systems apart from predominant involvement of muscles. Although falx calcification may occur in up to 13% of DM1 patients⁵, meningioma are extremely rare. There has only been one previous report of a histologically proven meningioma co-occurring with myotonic dystrophy.⁶ Our patient had myotonic dystrophy type 1 presenting with a typical pattern of muscular weakness and was coincidentally detected to have a spinal meningioma. In the previously reported case, a young woman with myotonia since childhood had recurrent and increasing headaches which prompted a cranial imaging. The cranial CT scan showed multiple calcified masses which were resected and histologically found to be meningioma.⁶ There was another report of right temporal meningioma coexistent with DM, but without histological confirmation.⁷ In our patient, the spinal meningioma was a chance discovery as there were no features suggestive of a myelopathy; the referring physician having missed the myotonia, ordered a dorsal spine MRI.

The CTG triplet expansion is located in the DMPK gene on chromosome 19q immediately adjacent to the homeodomain gene SIX5, and a reciprocal translocation of (1;19)(q21;q13.3) has been reported in patients of meningioma without neuromuscular disease.⁸ These cases including the one in this report probably indicate a role of DMPK gene in meningioma pathogenesis or progression, or a gene adjacent to the DMPK gene might be involved in meningioma formation, its expression being disrupted by a large triplet repeat expansion of DMPK.⁵

Whether the association of myotonic dystrophy with meningioma is related to the genetic defect or is a chance association, needs further analysis. However, in patients with atypical clinical features not conforming to the characteristic pattern of myotonic dystrophy, a search for craniospinal meningioma may be warranted.

REFERENCES

1. Harper PS. Myotonic dystrophy, 3rd ed. London: WB Saunders, 2004.
2. Ranum LPW, Day JW. Myotonic dystrophy: RNA pathogenesis comes into focus. *Am J Hum Genet* 2004; 74:793-804.
3. Huber SJ, Kissel JT, Shuttleworth EC, *et al.* Magnetic resonance imaging and clinical correlates of intellectual impairment in myotonic dystrophy. *Arch Neurol* 1989; 46:536-40.
4. Gourie Devi M, Choudhury JR, Vasanth A, *et al.* Correlation of clinical profile of myotonic

- dystrophy with CTG repeats in the myotonin protein kinase gene. *Indian J Med Res* 1998; 107:187-96.
5. Bachmann G, Damian MS, Koch M, *et al.* The clinical and genetic correlates of MRI findings in myotonic dystrophy. *Neuroradiology* 1996; 38:629-35.
6. Al-shekhee A, Sagar SM. A case of multiple meningioma and muscular dystrophy. *J Clin Neuromusc Dis* 2005; 7:70-1.
7. Konagaya M, Sakai M, Kuru S, *et al.* Evaluation of CT findings of patients with muscular dystrophy: with reference to cerebral vascular disease and cardiac complications. *No To Shinkei* 1999; 51:621-6.
8. Prempee T, Amornmarn R, Faillace WJ, *et al.* 1;19 translocation in human meningioma. *Cancer* 1993; 71:2306-11.